Neck & Cervical Assessment

Dr. Sahar Adham

Objectives:

At the end of this lab the student will be able to:

I . Demonstrate the ability to safely and accurately complete a comprehensive examination of Neck, and Lymph Nodes.

2. Demonstrate the ability to accurately & comprehensively document assessment data in organized and legible manner.

3. Evaluate assessment data to determine problems and identify client's concerns.

PREPARATION

I. Nurse
II. Environment
III. Client
IV. Equipment

Equipment:

I. Stethoscope
II. Cup of water

Subjective data:

1. Lumps or swelling
2. Neck injury
3. Neck pain, limitation of motion
4. History of neck surgery

Inspect neck for the following:

Appearance:

Normal :Symmetrical, centered head position

Movement:

Smooth, controlled movements; range of motion

(ROM) from:

Flexion = 45 degree

Extension = 55 degree

Lateral abduction = 40 degree

Rotation = 70 degree

- Abnormal : Asymmetrical , mass benign or malignant ,client may complains pain with flexion or rotation ,pain associated muscle spasm cause by meningitis , generalized discomfort may related to trauma, inflammation of muscle or vertebral disease

Palpation

Palpate trachea for position

(tracheal rings, cricoid & thyroid cartilage).

Midline position; symmetrical

Palpate thyroid for the following:

Position

Characteristics, landmarks

Midline ,Smooth, firm, no tender

Ask the client to drink sips of water normally thyroid move upward .The movement not visible in males the thyroid cartilage large or Adam's apple is more prominent than in females

Guidelines for palpating thyroid:

- Stand behind client & position hands with thumbs on nape of client's neck.

- Ask client to flex neck forward & to the right, & use fingers of the left hand to displace thyroid to the right.

- Palpate the right lobe using the right fingers while client swallows small sips of water.

- Repeat procedure to examine the left lobe.

(Note: ability to see or palpate the thyroid varies considerably with client thyroid size & body build).



A. Palpation of the thyroid from behind

B. Palpation of the thyroid from in front

Palpate cervical lymph nodes for the following:

Size & shape:	Cervical lymph nodes are usually not palpable. If palpable, they should be lcm or less & round.
Delineation:	Discrete
Mobility:	Mobile
Consistency:	Soft
Tenderness:	No tender

Lymph Nodes

1- Preaurical ✓

2- Postaurical ✓

3- Occipital ✓

4- Tonsillar ✓

5- Submandibular ✓

6- Submental ✓

7-Anterior cervical chain (deep cervical) ✓

8- Posterior cervical chain ✓

9- Supraclavical ✓

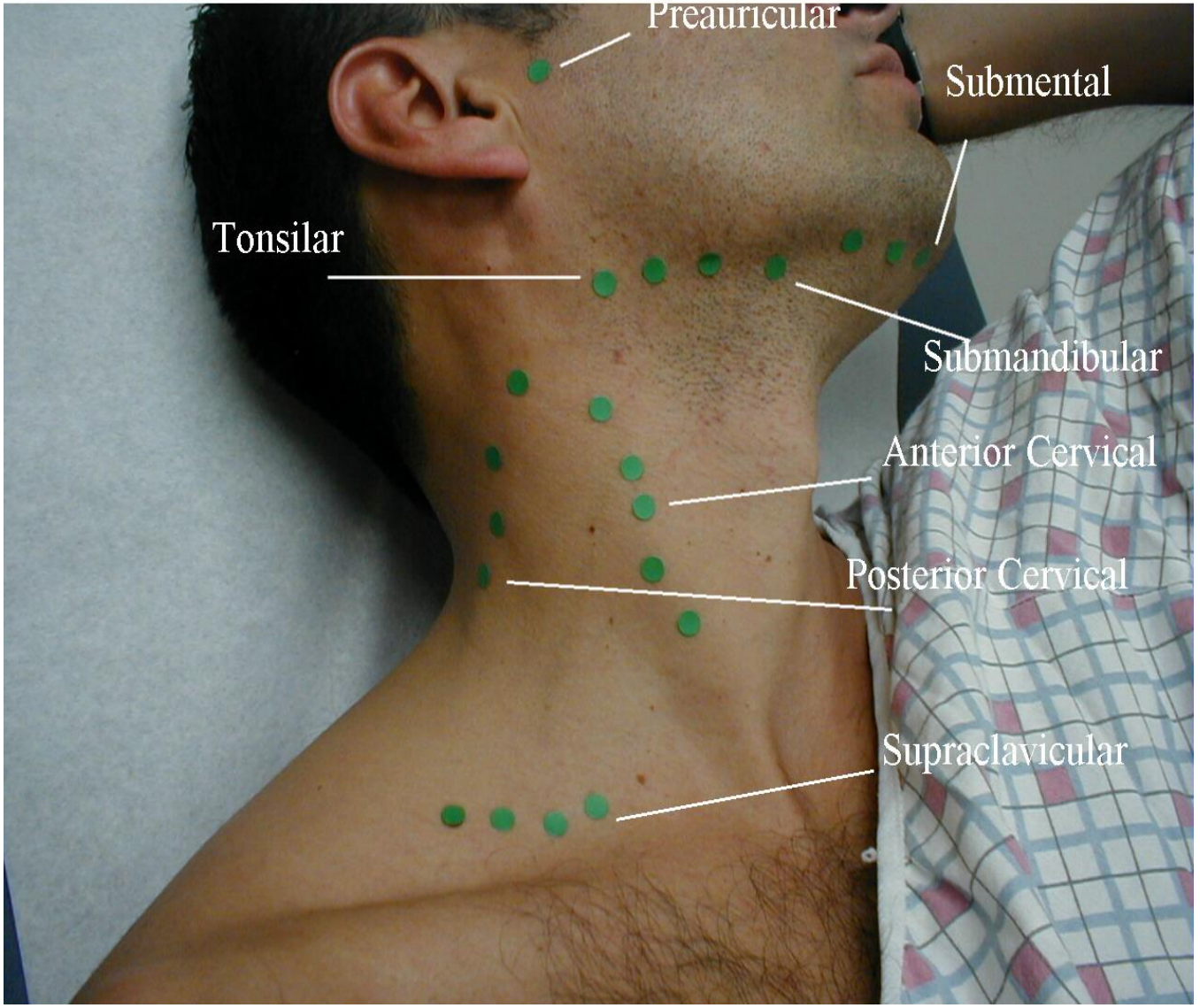
Preauricular
Submental
Tonsilar
Submandibular
Anterior Cervical
Posterior Cervical
Supraclavicular



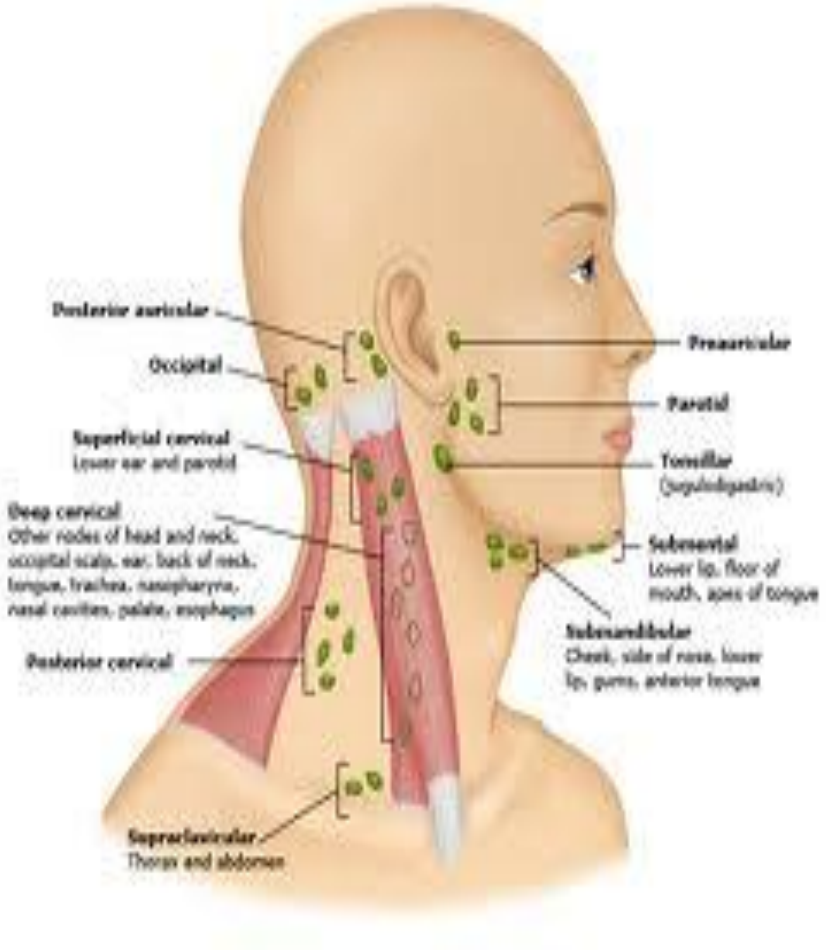
Posterior auricular
Occipital
Superficial cervical
Lower ear and parotid
Deep cervical
Other nodes of head and neck, occipital scalp, ear, back of neck, tongue, trachea, nasopharynx, nasal cavities, palate, esophagus
Posterior cervical
Supraclavicular
Thorax and abdomen
Preauricular
Parotid
Tonsillar
(Jugulodigastric)
Submental
Lower lip, floor of mouth, apex of tongue
Submandibular
Cheek, side of nose, lower lip, gums, anterior tongue


M. Esternocleid
omastoideo
M. esplenio
M. Elevador
del hombro
Mm. escalenos
M. Trapecio
M. digástrico
Hueso hioides
M. tirohioideo
M. omohioideo
M.Esternohioideo

Ascultation

Use bell to assess bruit sound