Anatomy

Lecture 3

INTEGUMENTARY SYSTEM

skin is crucial for human survival. Perhaps its most obvious task is to define the body's structure:

1. joining forces with the muscular and skeletal systems to build the body's framework. But that's just one small part of the skin's role.
2. This thin, self-regenerating tissue also separates the internal from the external environment,
3. protects the body from invasion by harmful substances,
4. and helps maintain homeostasis.
5. In addition, sensory nerve receptors in the skin gather information about the outside world
6. while its flexibility and ability to stretch permit freedom of movement. Last but not least,
7. changes in the skin can signal diseases or disorders in other body systems.

For these reasons and more, the skin and its appendages (hair, nails, and skin glands)—collectively known as the **integumentary system**.

Structure of the Skin

The skin, also called the **cutaneous membrane**, consists of :

1.The **epidermis**—the outermost layer— consists of stratified squamous epithelial tissue. It contains no blood vessels; instead, it obtains oxygen and nutrients by diffusion from the dermal layer beneath it.

2.The **dermis**—is composed of connective tissue. It contains collagen fibers (which strengthen the tissue), elastin fibers (which provide elasticity) and reticular fibers (which bind the collagen and elastin fibers together). The dermis contains an abundance of blood vessels , sweat glands, sebaceous glands, and nerve endings. Hair follicles are also embedded in the dermis. Finger-like projections, called **papillae**, extend upward from the dermis. These projections interlock with downward waves on the bottom of the epidermis, effectively binding the two structures together.

3.the **hypodermis**. Made of loose connective(areolar) tissue and adipose tissue, the hypodermis binds the skin to the underlying tissue. Hypodermis that's composed mostly of adipose tissue is called subcutaneous fat. This layer of fat helps insulate the body from outside temperature changes; it also acts as an energy reservoir

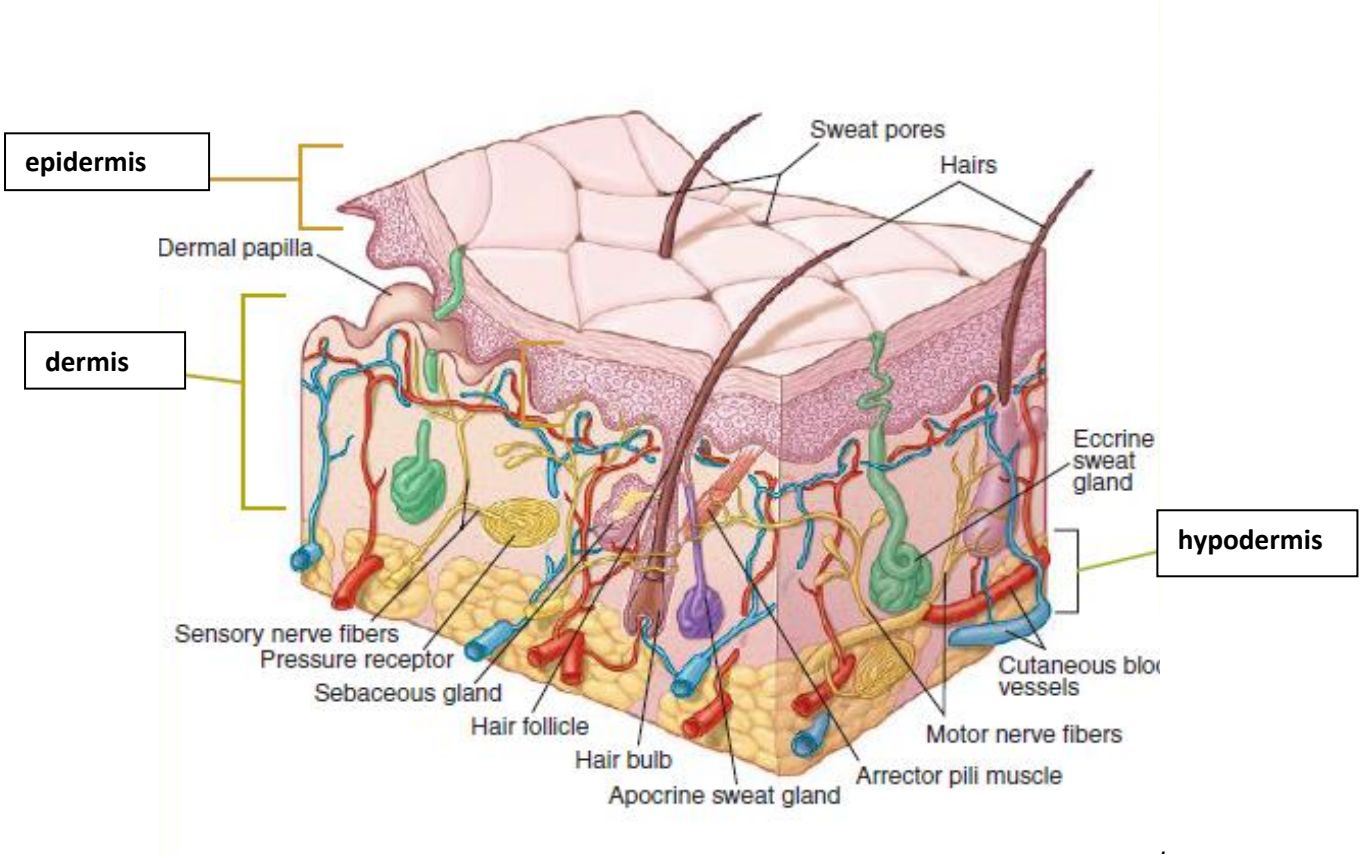

Skin Color

Scattered throughout the basal layer of the epidermis are cells called **melanocytes**. These special cells produce a substance called **melanin**, which accumulates in the cells of the epidermis. There are two types of melanin: a reddish *pheomelanin* and a brown-black *eumelanin.*

A person's skin color is determined by the amount, and type, of melanin—not the number of melanocytes. (Infact, persons of all races have about the same number of melanocytes. The cells in dark-skinned people produce more melanin, and the melanin is broken down more slowly.)

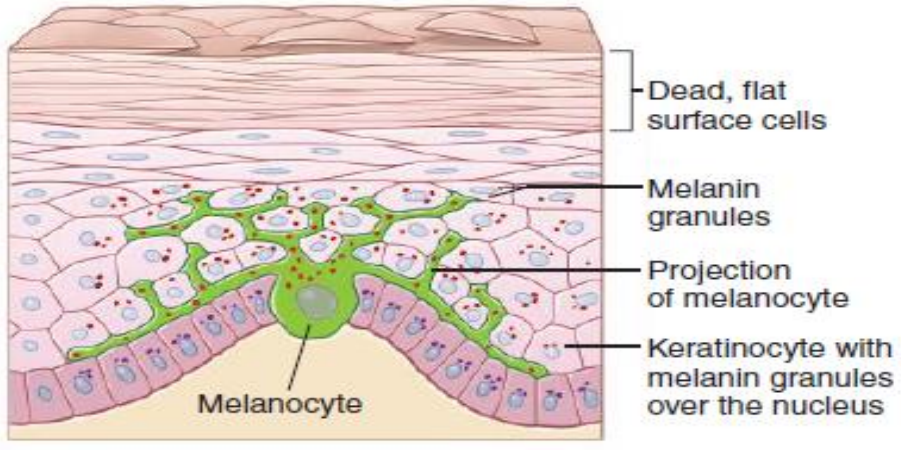

Melanocytes, which have long projections reaching between cells, release melanin.

- The keratinocytes then bring the melanin into their cells.
- The melanin forms a cap over the top of the cell nucleus to protect it from exposure to the harmful ultraviolet rays of the sun.
- Prolonged exposure to sunlight stimulates the cells to secrete more melanin. This protects the cell's nucleus and also darkens the skin.

Note :When ultraviolet radiation reaches the nucleus of the cell, it damages the cell's DNA and can lead to skin cancer.

A yellow pigment called carotene is also stored in skin tissue. Eating large quantities of foods containing carotene (such as carrots) can give the skin a yellow tint.

Appendages of the Skin

The appendages of the skin are hair, nails, and glands.

Hair

Hair occurs everywhere on the body except for a few locations: the palms and soles, lips, nipples, and some areas of the genitals. In some locations, hair has a protective role: the eyelashes and eyebrows keep perspiration out of the eyes; hair in the nostrils filters out dust; and the hair on the head provides insulation against heat and cold.

The **shaft** is the part of the hair that extends above the skin's surface.

Each hair lies within a sheath of epidermis called a **hair follicle**. Hair follicles have a rich nerve and blood supply.

Buried in the dermis is the hair **bulb** or **root**; this is the lowest part of the hair and is where growth occurs.

At the base of the hair is a cluster ofconnective tissue and blood vessels called the **papilla** that nourishes each hair.

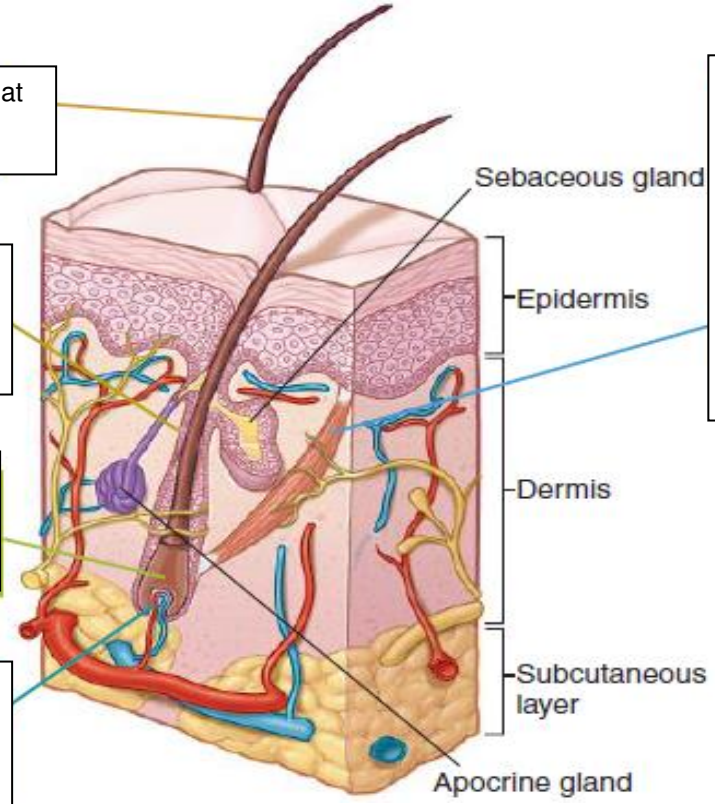

Attached to each hair follicle is a small bundle of smooth muscle called the **arrector pili** muscle. Cold temperatures, or emotions such as fear, cause the muscle to contract. When it does, the hair becomes more upright, sometimes called "standing on end

Nails

Nails consist of densely packed, heavily keratinized epithelial cells.

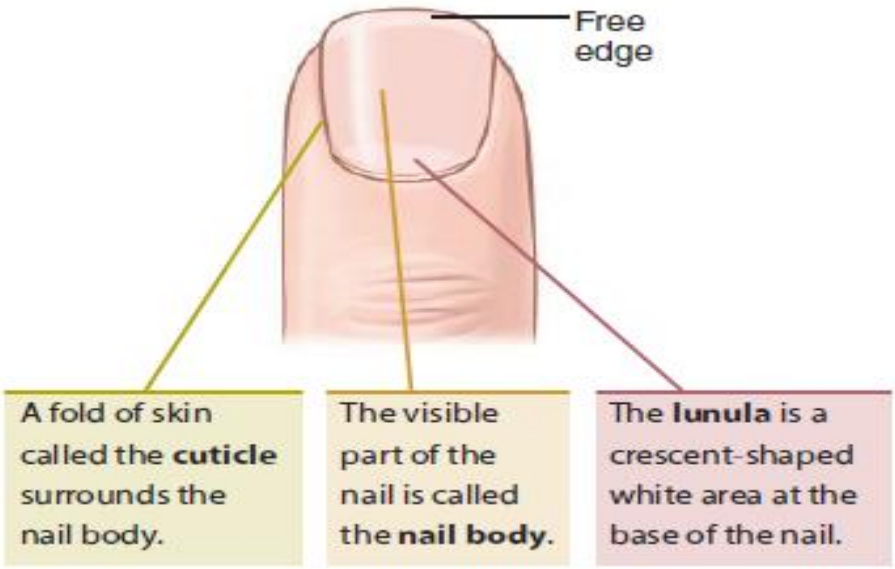

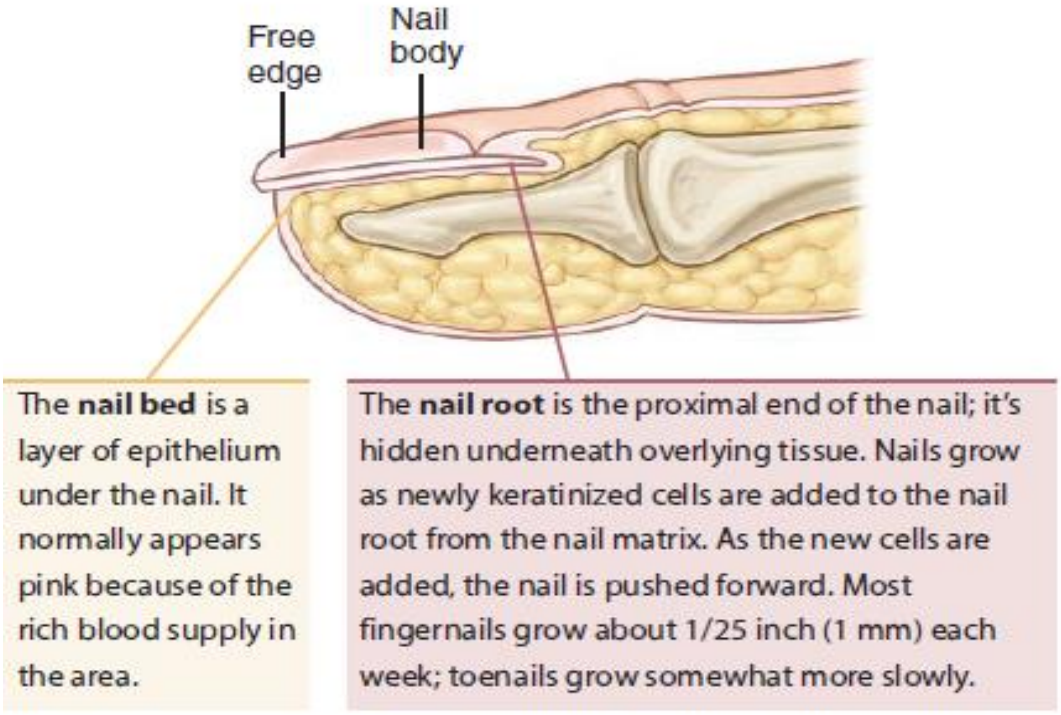

Glands

The glands associated with the skin include sweat glands, sebaceous glands, and ceruminous glands.

Sweat Glands

These are the most numerous of the skin glands.

Eccrine glands

• Contain a duct that leads from a secretory portion (consisting of a twisted coil in the dermis), through the dermis and epidermis, and onto the skin's surface.These glands are widespread throughout the body, but are especially abundant on the palms, soles, forehead, and upper

Torso .Produce a transparent, watery fluid called *sweat*, which contains potassium, ammonia, lactic acid, uric acid, and other wastes. Sweat plays a chief role in helping the body maintain a constant core temperature and also helps the body eliminate wastes.

Apocrine glands

• Contain a duct that leads to a hair follicle (as opposed to opening onto the skin's surface).Are located mainly in the axillary and anogenital (groin) regions. Are scent glands that respond to stress and sexual stimulation. Begin to function at puberty

Sebaceous glands, which open into a hair follicle, secrete an oily substance called sebum. Sebum helps keep the skin and hair from drying out and becoming brittle.

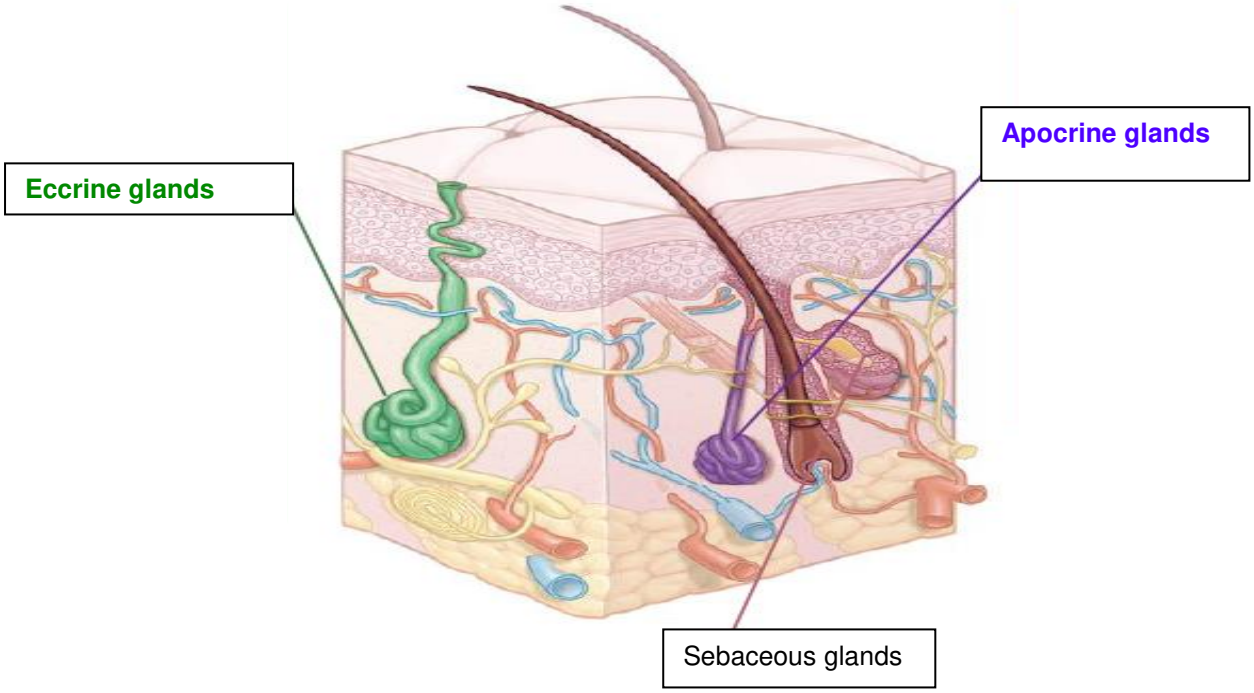

Ceruminous Glands

Ceruminous glands, which exist in the external ear canal, secrete a waxy substance called **cerumen**, or ear wax. Cerumen helps keep the ear canal from drying out. However, excess cerumen can accumulate in the ear canal and harden, diminishing hearing.

Life lesson: Burns

Burns can be caused by fire, hot water, steam, electricity, chemicals, and sunlight. Considering the skin's crucial role in protecting against infection, controlling fluid loss, and thermoregulation, it's easy to understand the seriousness of severe or extensive burns. In fact, following a serious burn, a patient may lose as much as 75% of his circulating fluid volume in the first few hours, placing that person at risk for circulatory collapse and cardiac arrest. Another complication of burns is the development of eschar—the dead tissue resulting from a burn. Besides secreting toxins and promoting bacterial growth, eschar can restrict circulation. Burns are classified according to their depth: in other words, the number of tissue layers affected by the burn.

Classification of burns

First-degree burn

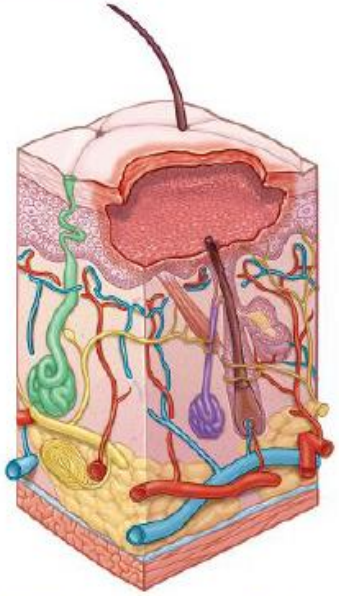

Partial-thickness bum: superficial

- Involves only the epidermis
- Causes redness, slight swelling, and pain
- Often results from sunlight (sunburn)

Second-degree burn



Partial-thickness burn: deep

- Involves the epidermis as well as part of the dermis
- Results in blisters, severe pain, and swelling
- May result in scarring
- May appear red, white, or tan

Third-degree burn

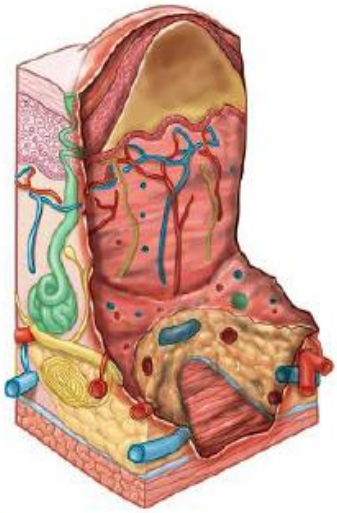

Full-thickness burn

- Extends through the epidermis and dermis and into the subcutaneous layer
- May not be painful initially because of the destruction of nerve endings
- May appear white or black and leathery
- Often requires skin grafts