Anatomy
Lecture 4

BONES & BONE TISSUE

The 206 bones in the adult human body are actually dynamic living tissue. Bone constantly breaks down and rebuilds itself, not just during the growth phases of childhood, but throughout the life span. Bone is filled with blood vessels, nerves, and living cells; in addition, its interaction with other body systems is necessary not only for movement, but also for life itself.

Bone fulfills multiple roles in the body, including:

- **Shape** , **Support** , **Protection** ,**Movement** ,**Blood production**
- **Electrolyte balance:** Bones store and release minerals such as calcium and phosphorus—necessary ingredients for a variety of chemical reactions throughout the body.
- **Acid-base balance:** Bone absorbs and releases alkaline salts to help maintain a stable pH.

Classification of Bones

Bones perform a variety of functions. It's those functions that dictate the bone's shape. This variety in the shape of bones lends itself to a classification system.

1. Long bones

As the name suggests, these bones have a very long axis and are longer than they are wide. Examples include the femur of the thigh and the humerus of the arm. Long bones work like levers to move limbs.

2. Short bones

About as broad as they are long, these tend to be shaped like cubes. Examples include the carpal bones of the wrist and the tarsal bones of the ankle.

3. Flat bones

These thin, flat, often curved bones protect organs, such as the bones of the skull, the ribs, and the breastbone (sternum). Others, such as the shoulder blades (scapulae), provide a large surface area for the attachment of muscles.

4. Irregular bones

Often clustered in groups, these bones come in various sizes and shapes. Examples include the vertebrae and facial bones. *Sesamoid bones* are small bones embedded in tendons. The kneecap is an example of a sesamoid bone

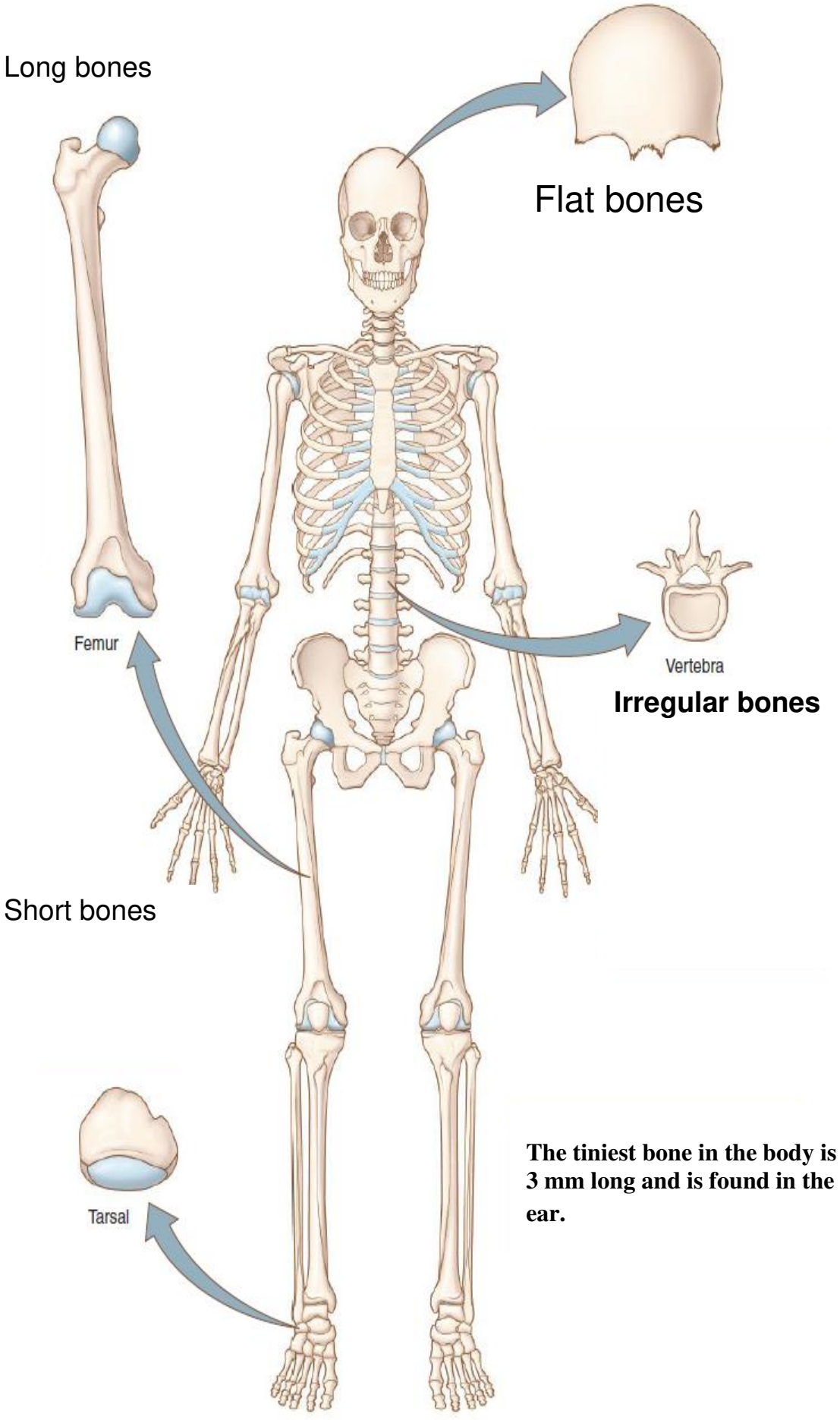

The tiniest bone in the body is 3 mm long and is found in the ear.

Parts of a Long Bone

Long bones consist of several key structures:

1. The head of each end of a long bone is the **epiphysis**. The bulbous structure of the epiphysis strengthens the joint; it also allows an expanded area for the attachment of tendons and ligaments.
2. Covering the surface of the epiphysis is a thin layer of hyaline cartilage called **articular cartilage**. This cartilage, along with a lubricating fluid secreted between bones, eases the movement of the bone
3. The central shaft-like portion of the bone is called the **diaphysis**. Thick, compact bone makes up this hollow cylinder, giving the bone the strength it needs to support a large amount of weight.
4. A dense fibrous membrane called the **periosteum** covers the diaphysis. Periosteum weave together with the fibers of tendons. (Tendons attach muscle to bone.)This arrangement ensures a strong connection between muscle and bone.
5. • In children, the medullary cavity is filled with blood cell-producing **red bone marrow**. In adults, most of this marrow has turned to **yellow marrow**, which is rich in fat..

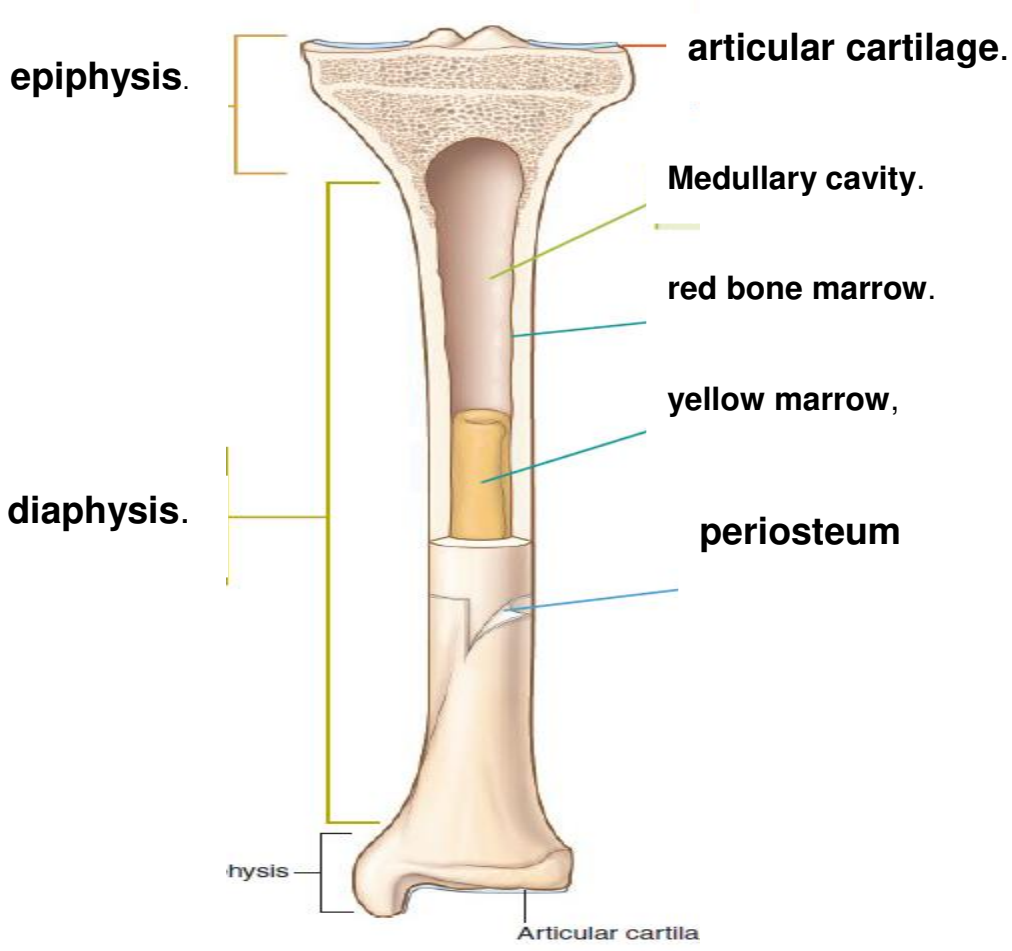

NOTE :

In growing children, a layer of cartilage, called the epiphyseal plate or growth plate, separates the epiphysis from the diaphysis at each end of a long bone. Once growth stops, the plate is replaced by an epiphyseal line.

Types of Bone Tissue

Not all bone, or osseous tissue, has the same characteristics:

- Some osseous tissue is light and porous; this is spongy, or cancellous, bone. **Spongy bone** is found in the ends of long bones and in the middle of most other bones; it is always surrounded by the more durable compact bone.
- Other osseous tissue—called **compact bone**—is dense and solid. Its density offers strength, which is why it forms the shafts of long bones and the outer surfaces of other bones.

Bone Marrow

Bone marrow is a type of soft tissue that fills the medullary cavity of long bones as well as the spaces of spongy bone. There are two types of bone marrow:

1. Red bone marrow: This is the bone marrow charged with producing red blood cells. Nearly all of a child's bones contain red bone marrow.

2. Yellow bone marrow: Over time, red marrow is gradually replaced with fatty yellow marrow. Because its marrow cells are saturated with fat, yellow marrow no longer produces blood cells. However, in cases of severe, chronic blood loss or anemia, yellow marrow can change back into red marrow.

NOTE: In an adult, red bone marrow can be found only in the ribs, sternum, vertebrae, skull, pelvis, and the upper parts of both the humerus (arm) and femur (thigh). All other bones contain yellow marrow.

Skeletal system

While most adults have 206 bones**,** of these bones 80 comprise the upright, central supporting axis of the body, which includes the skull, rib cage, and vertebral column. This is the **axial skeleton**.

The other 126 bones make up the bones of the limbs and the pelvic and shoulder area. This is the **appendicular skeleton**.

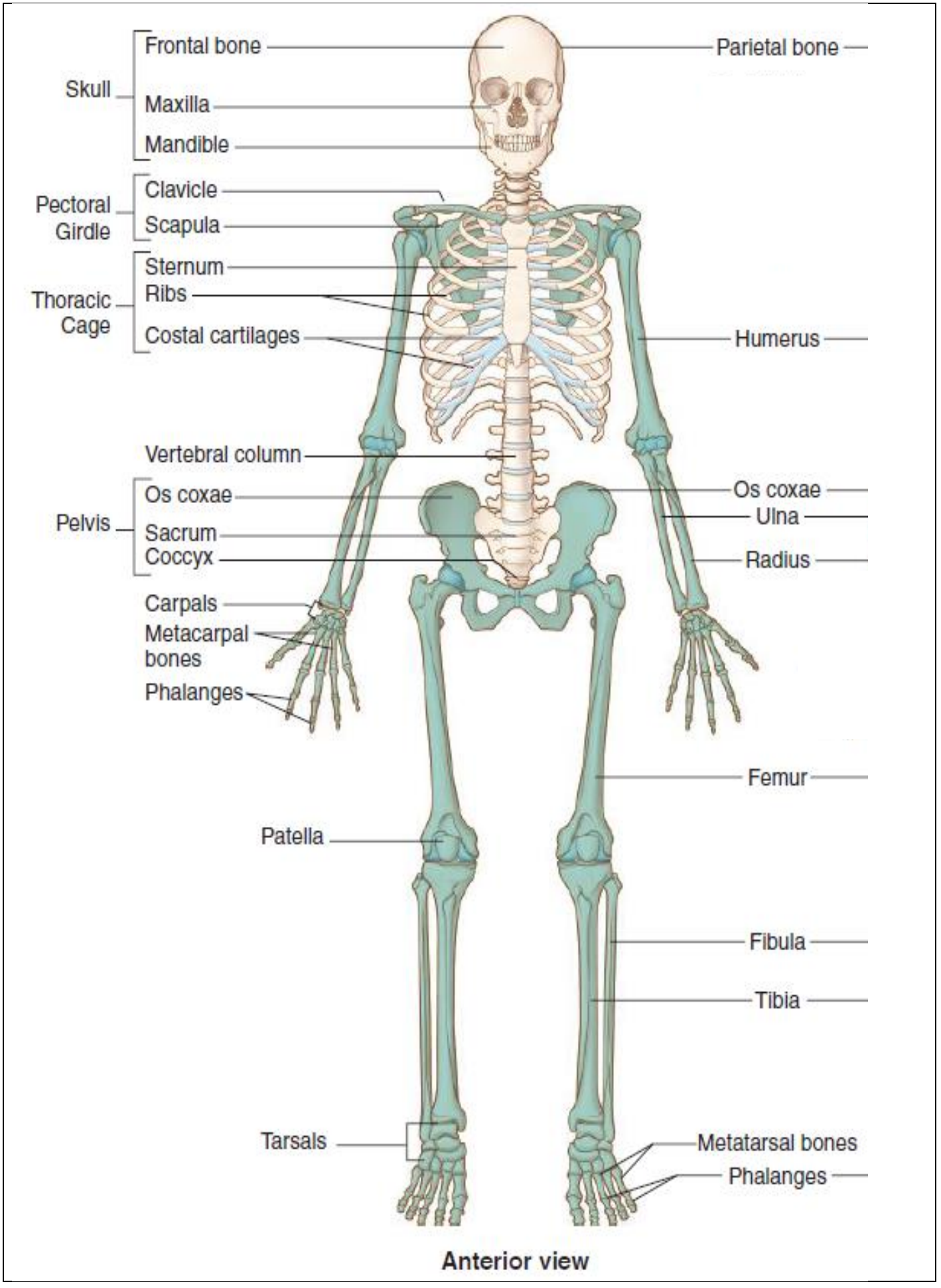

Anterior view

Cranium and Suture Lines

The **cranium** is the bony structure housing the brain. It consists of eight **cranial bones** which join together at immovable joints called **sutures.**

Parietal bones (2 bones): Join together at the top of the head to form the top and sides of the cranial cavity

Frontal bone (1 bone): Forms the forehead and the roof of the eye sockets

Occipital bone (1 bone): Forms the rear of the skull

Temporal bones (2 bones): also contain the structures of the inner and middle ear, including the:

- **External auditory meatus** (an opening into the ear)
- **Mastoid process** (aprominent lump behind the ear)
- **Zygomatic arch** (cheekbone)
- **Styloid process** (an attachment point for several neck muscles)

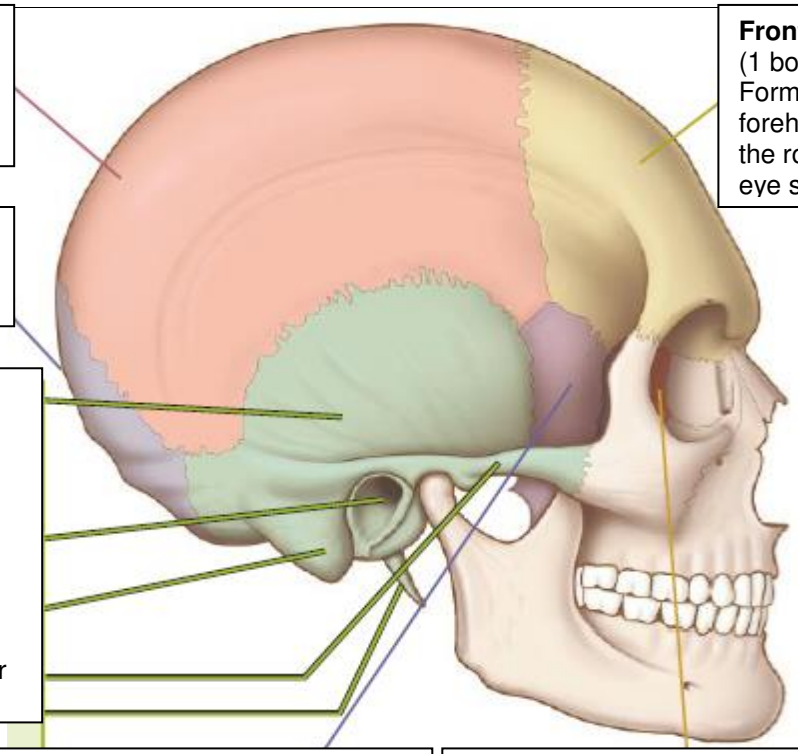

Sphenoid bone (1 bone): Forms a key part of the cranial floor as well as the floor and side walls of the orbits

Ethmoid bone (1 bone): Contributes to the walls of the orbits, the roof and walls of the nasal cavity, and the nasal septum

The **coronal suture**

The **lambdoidal suture**

The **squamous suture**

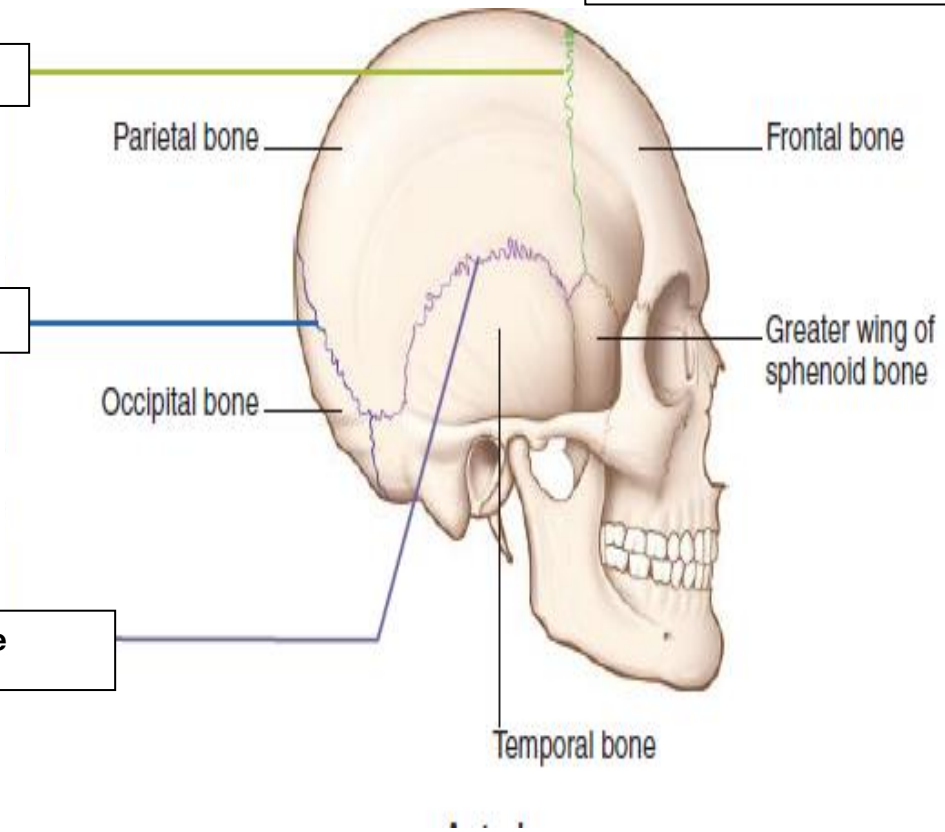

Facial Bones

The 14 bones of the face perform several functions. They support the teeth, provide an attachment point for the muscles used in chewing and for facial expression, form part of the nasal and orbital cavities, and also give each face its unique characteristics.

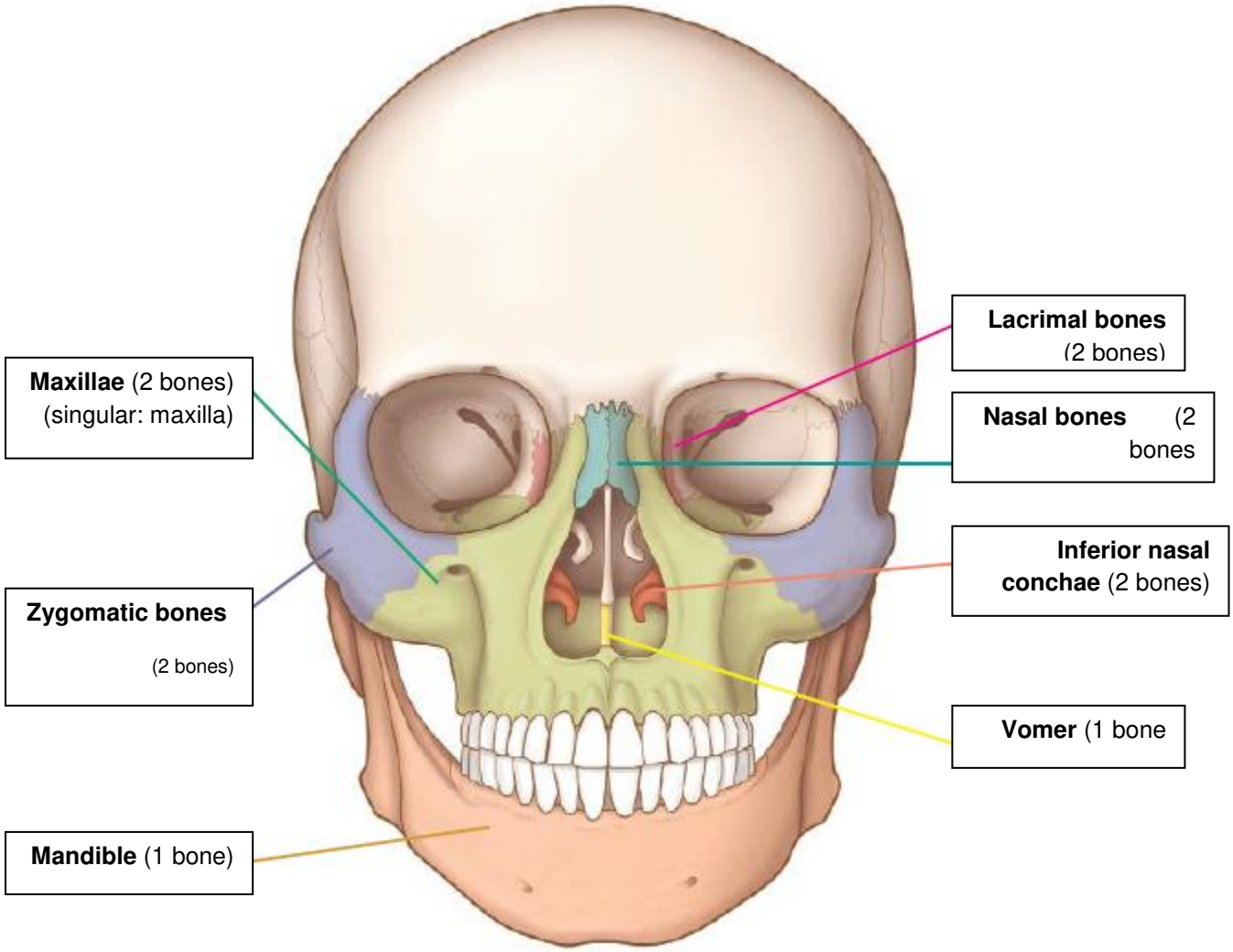

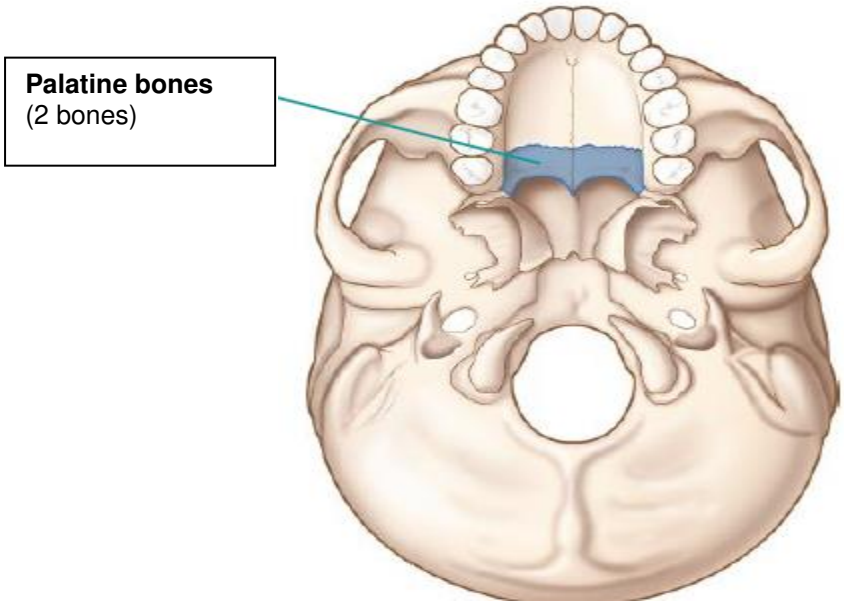

Bones Associated with the Skull

Several other bones are associated with the skull but not considered a part of the skull. These include the three bones of the middle ear. Called **auditory ossicles**, these bones are named the **malleus** (hammer), **incus** (anvil), and **stapes** (stirrup).

Hyoid Bone

Another bone associated with the skull is the **hyoid bone**: a U-shaped bone that sits between the chin and the larynx. The hyoid bone—which is the only bone that doesn't articulate with any other bone—serves as an attachment point for muscles that control the tongue, mandible, and larynx.

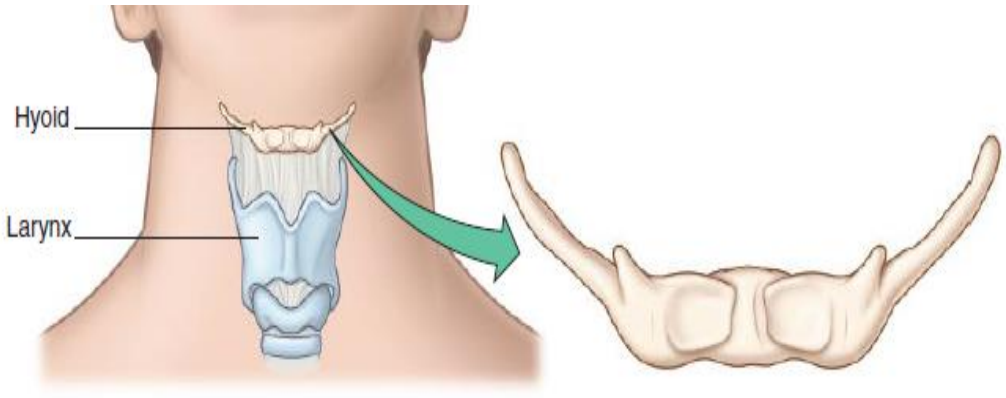

Sinuses

The skull contains several cavities, which include the **paranasal sinuses**. The four pairs of sinuses—which are named for the bones in which they reside—open into the internal nose. Filled with air, they lighten the skull and act as resonators for sound production. The frontal, maxillary, and ethmoid sinuses have well-defined shapes. The sphenoid sinuses are more like sinus cells, having a honeycombed shape.

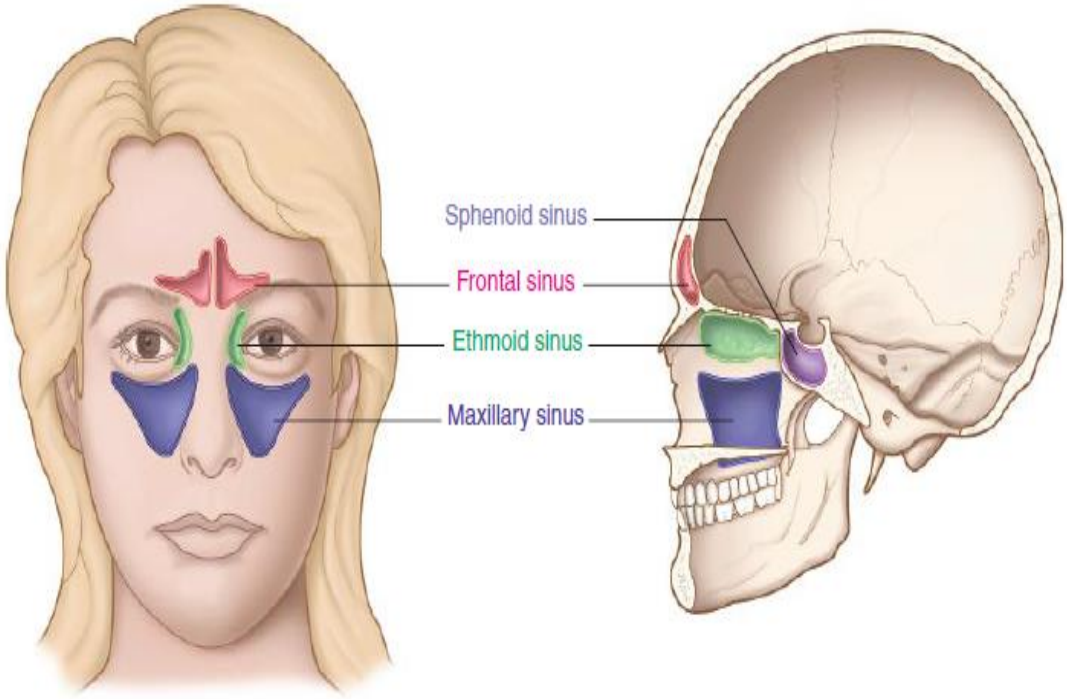

The Infant Skull

An infant's skull varies from that of an adult in two key ways:

1. The suture lines in the skull have not yet fused. Because the suture lines haven't fused, the bones of the skull can shift and overlap, molding the head so the infant can pass through the birth canal. The un-fused suture lines also allow for the rapid brain growth that occurs during infancy.

2. The infant's skull contains fontanels. The areas between the un-fused bones, which are covered by fibrous membranes, are called fontanels. Soft to the touch, it's possible to palpate pulsations in these areas. Over time, the fontanels shrink and usually close completely by age two years.

