Anatomy
Lecture 5

The vertebral column

The vertebral column—a flexible structure consisting of 33 vertebrae—holds the head and torso upright, serves as an attachment point for the legs, and encases the spinal cord. Its unique structure allows the body to bend forward, backward, and sideways.

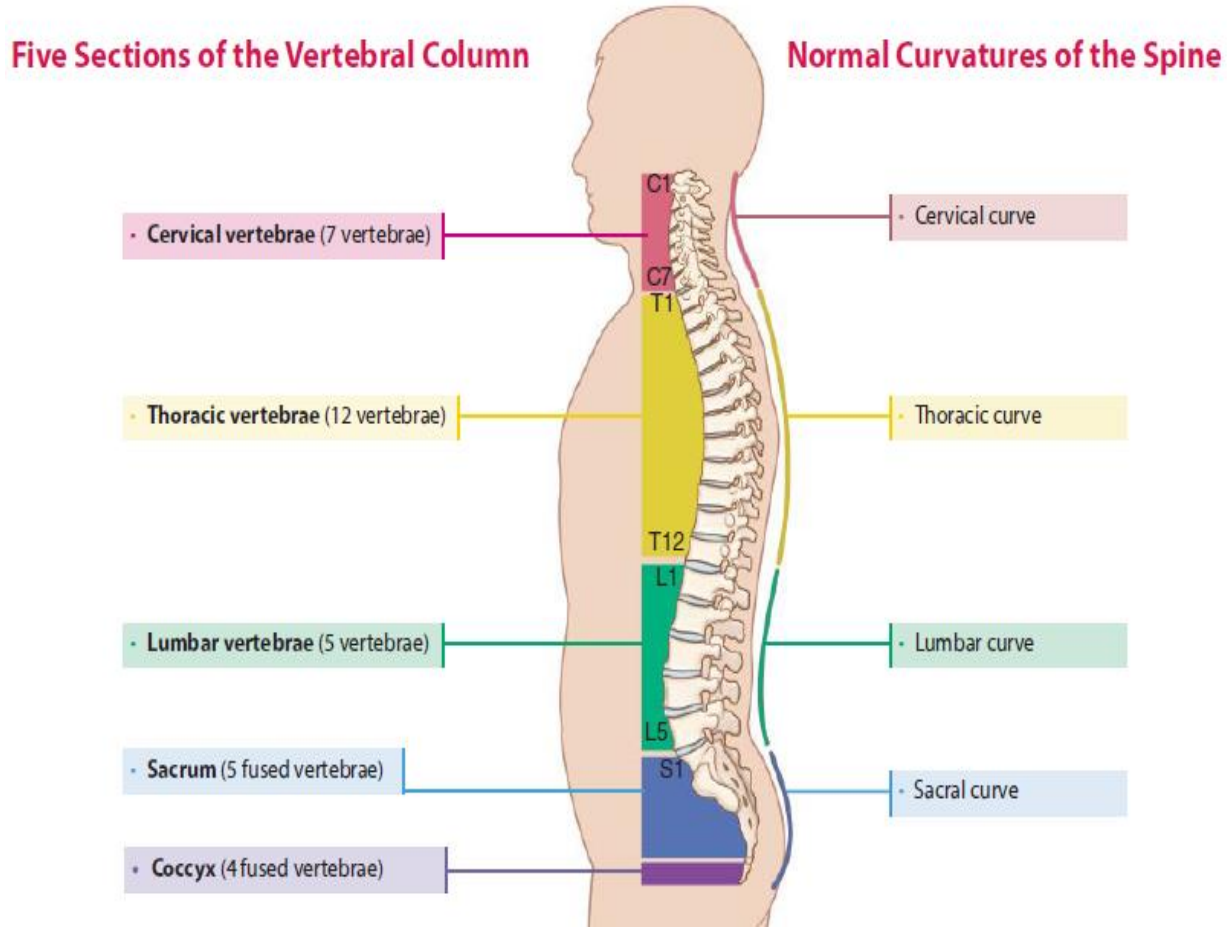

Vertebrae Characteristics

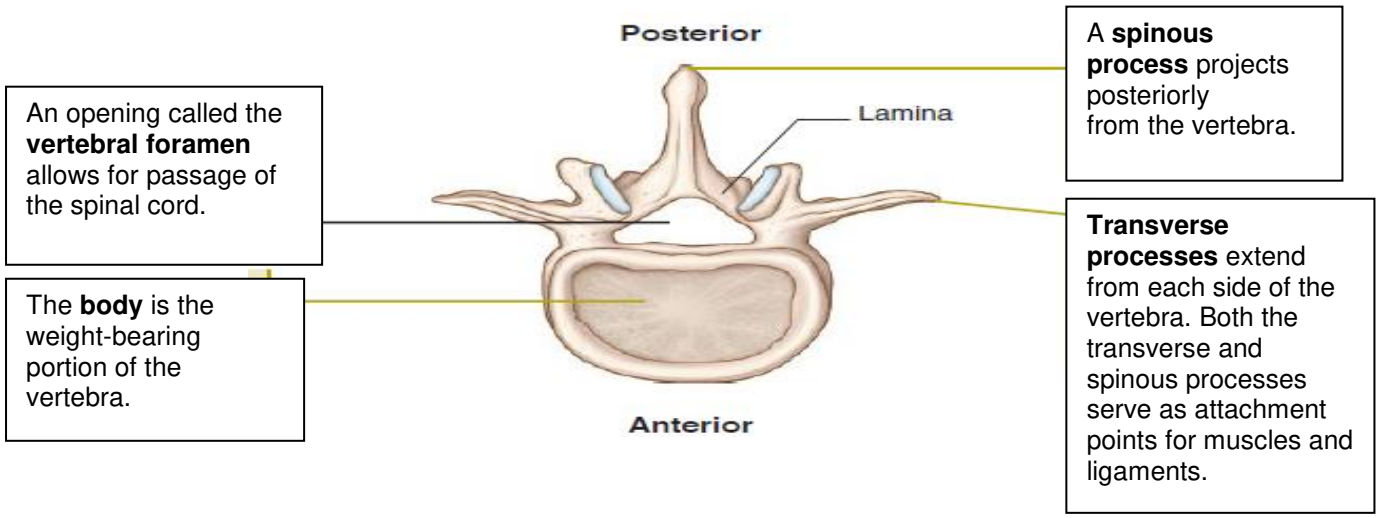

Intervertebral Disc

In between each vertebra is an **intervertebral disc**. Designed to support weight and absorb shock, the intervertebral disc consists of two parts:

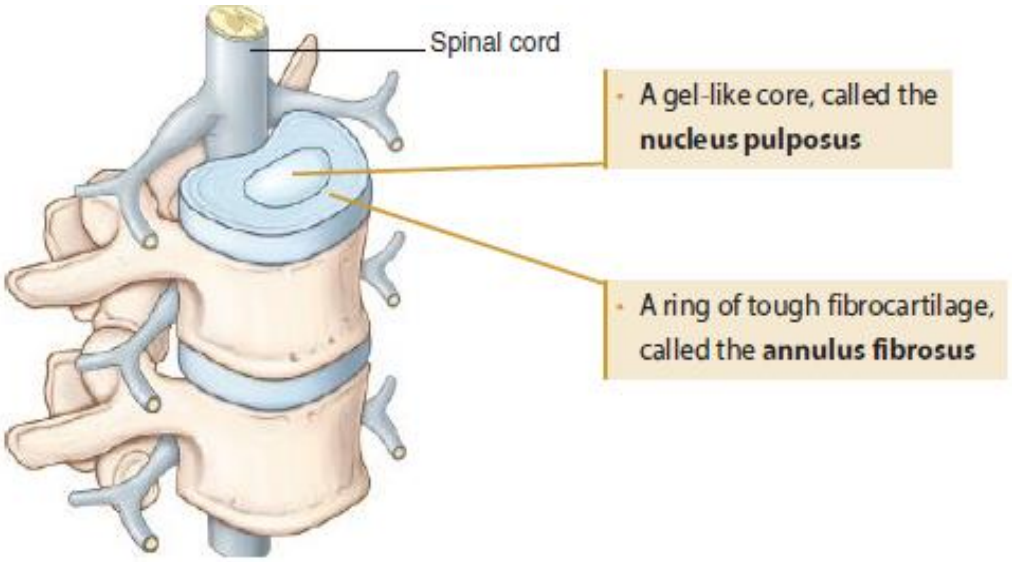

The Thoracic Cage

The thoracic cage consists of the thoracic vertebrae, the sternum, and the ribs. These bones form a cone-shaped cage that surrounds and protects the heart and lungs and provides an attachment point for the pectoral girdle (shoulder) and upper limbs. Expansion and contraction of the thoracic cage causes the pressure changes in the lungs that allow breathing to occur.

Sternum
has three regions
1. **Manubrium**:

2. **Body**: This is the longest portion.

3.**Xiphoid process**: provides an attachment point for some abdominal muscles.

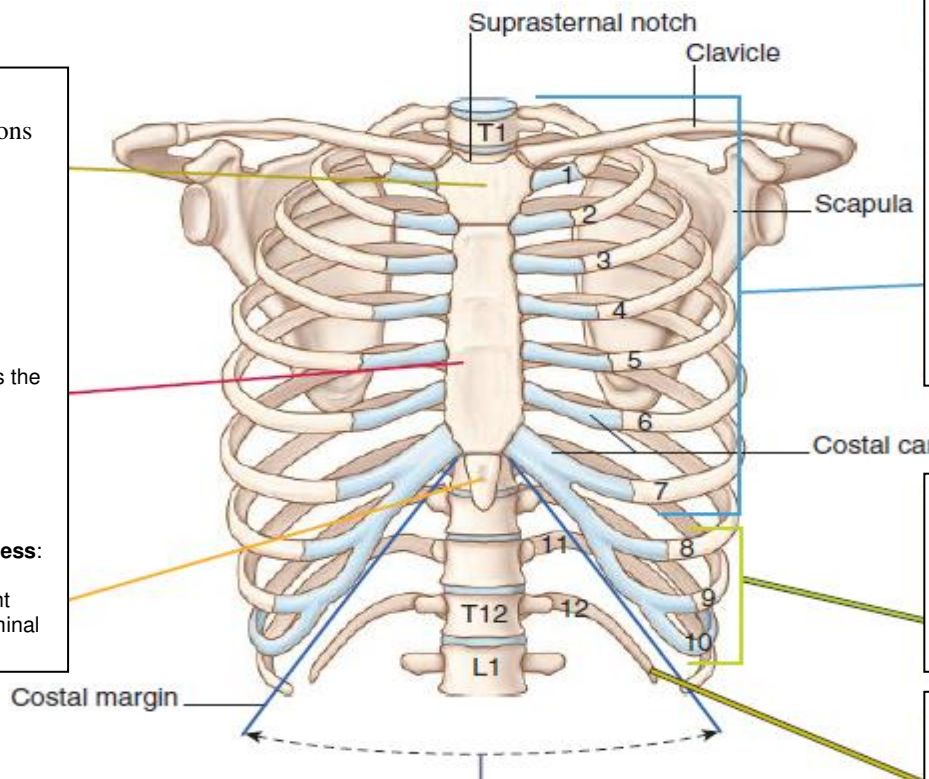

Ribs
Twelve pairs of ribs attach to the vertebral column.

Ribs 1 to 7, called **true ribs**, attach to the sternum by a strip of hyaline cartilage called **costal cartilage**.

Ribs 8, 9, and 10 attach to the cartilage of rib 7; these ribs, as well as ribs 11 and 12, are called **false ribs**.

Ribs 11 and 12, called **floating ribs**, do not attach to any part of the anterior thoracic cage.

The lower edges of the thoracic cage are called the **costal margins**.

Pectoral Girdle

Also called the **shoulder girdle**, the **pectoral girdle** supports the arm. The two pectoral girdles—one on each side of the body—consist of a **clavicle** (collarbone) and a **scapula** (shoulder blade).

A slightly S-shaped bone, the **clavicle** articulates with the sternum and the scapula and helps support the shoulder.

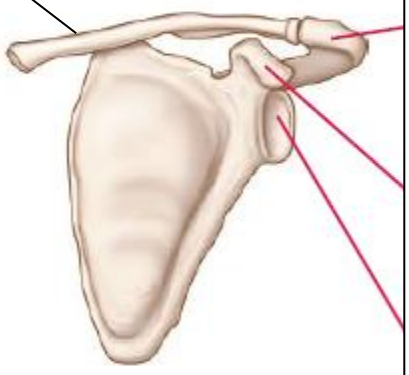

the **scapula** lies over ribs 2 to 7. The lateral portion of this triangle-shaped bone has three main features.

- The **acromion process**: This extension of the scapula articulates with the clavicle; it is the only point where the arm and the scapula attach to the rest of the skeleton.
- The **coracoid process**: This finger-like process provides a point of attachment for some of the muscles of the arm.
- The **glenoid cavity**: This shallow socket articulates with the head of the humerus (upper arm bone).

Upper Limb

The upper limb, or arm, consists of the humerus (upper arm bone), the radius and the ulna (the bones of the lower arm), and the carpals (the bones of the hand).

The **humerus** is the long bone of the upper arm. It contains

- **Head**: ; it articulates with the glenoid cavity of the scapula.
- **Olecranon fossa**: This is a depression on the posterior side of the humerus.
- **Olecranon process:** it slides in the olecranon fossa when the arm is extended.



Posterior view of elbow

the **radius**, is located on the same side as the thumb.

- The **proximal head** of the radius is a distinctive disc that rotates on the humerus when the palm is turned forward and back.
- The **radial tuberosity** is where the biceps muscle attaches to the bone

The **ulna** is the other bone of the lower arm; it is longer than the radius

The **styloid processes of the radius and ulna** are the bony bumps that can be felt at the wrist.

Anterior view of right arm

Hand

The **hand** consists of the wrist, palm, and fingers.

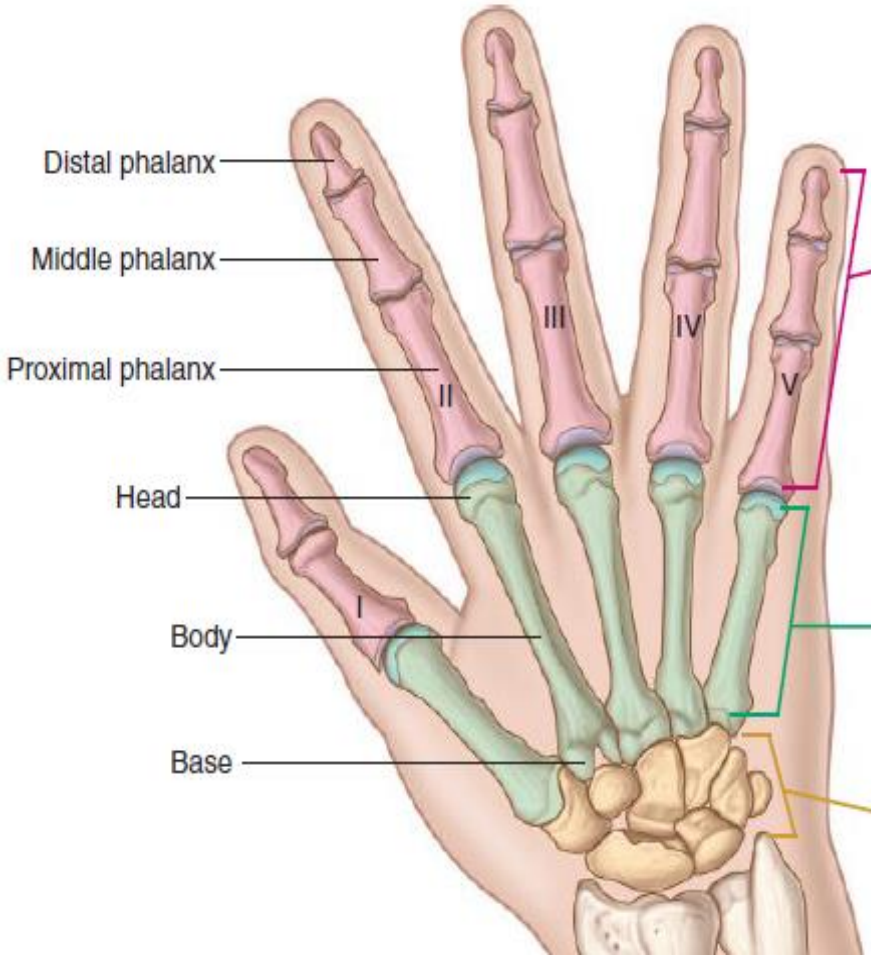

The fingers are formed by bones called **phalanges**. (The singular form of *phalanges* is *phalanx*.) The thumb contains two phalanges; the rest of the fingers contain three.

Five **metacarpal bones** form the palm of the hand. The proximal end is called the base, the shaft is called the body, and the distal end is called the head.

Eight **carpal bones**—arranged in two rows of four bones—form the wrist. These bones allow the wrist to move back and forth as well as side to side.

Pelvic Girdle

Each of the two large bones of the hip is called an **os coxae**; it may also be called a **coxal bone** or **innominate bone**. Together they form what's known as the **pelvic girdle**: the foundation of the pelvis. The os coxae is not a single bone; rather, it consists of three bones fused together.

The combination of the os coxae and the sacrum is known as the **pelvis**. The pelvis supports the trunk, provides an attachment point for the legs, and also protects the organs of the pelvis (including the lower colon, reproductive organs, and urinary bladder).

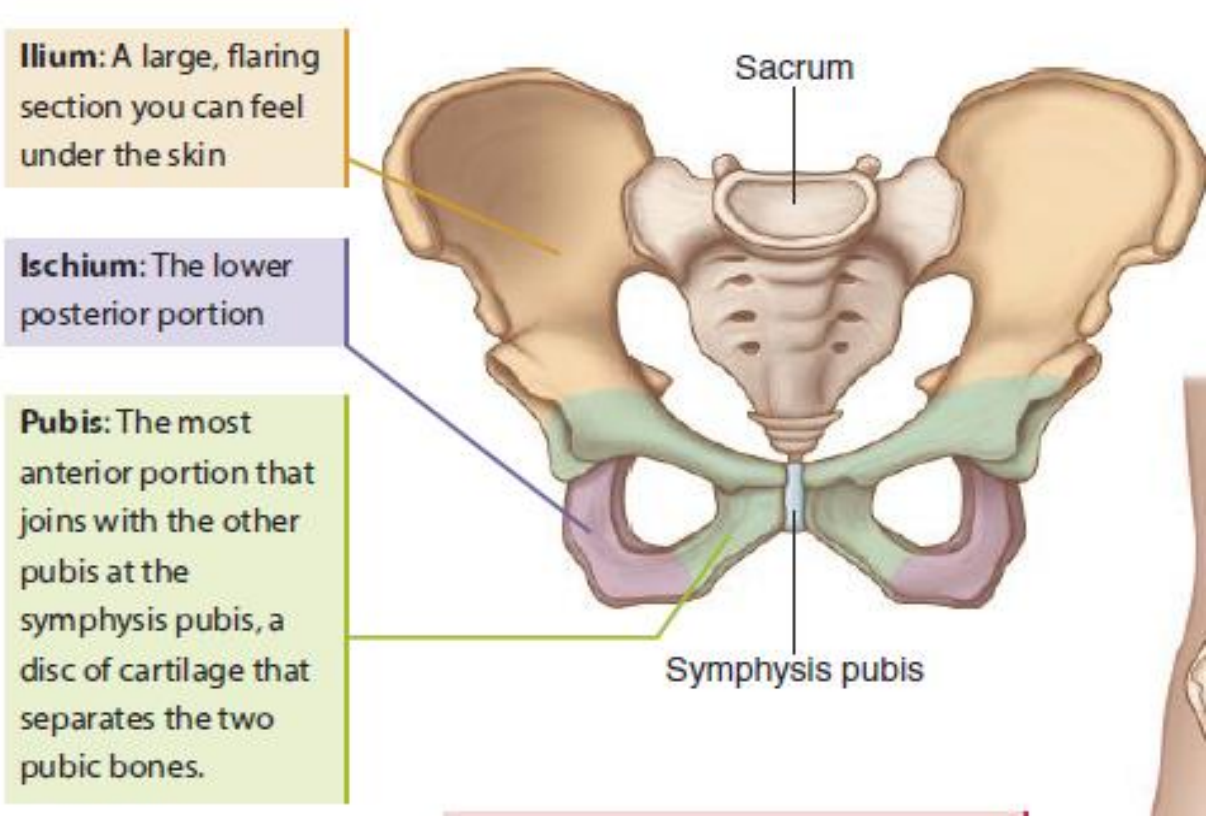

The male and female pelvises have a number of differences, mainly because the female pelvis is adapted for pregnancy and childbirth.

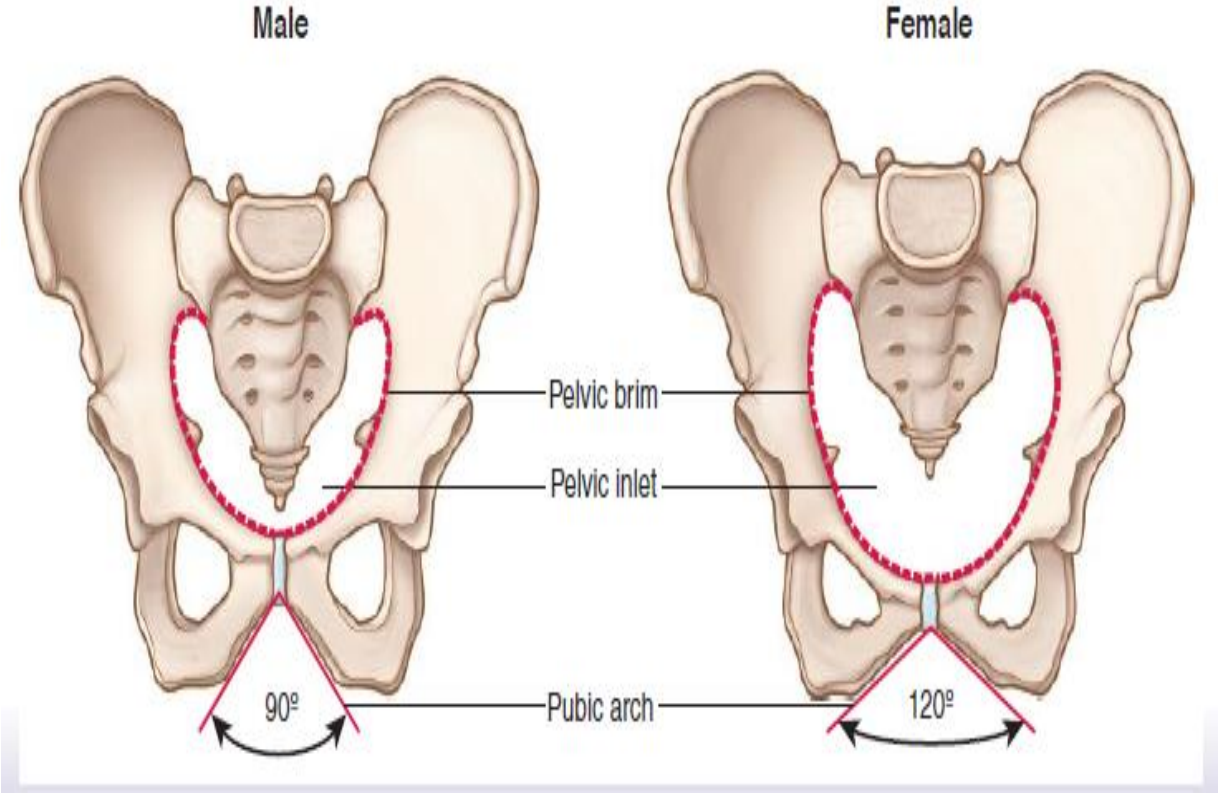

Lower Limb

The bones of the lower limb—which consist of the femur (thigh bone), patella (kneecap), tibia and fibula (bones of the lower leg), and foot—join with the pelvis to give the body a stable base. More importantly, the bones of the lower limb are articulated in such a way as to allow the body to move.

Femur

The longest and strongest bone in the body, the femur articulates with the acetabulum of the pelvis to form a ball-and-socket joint.

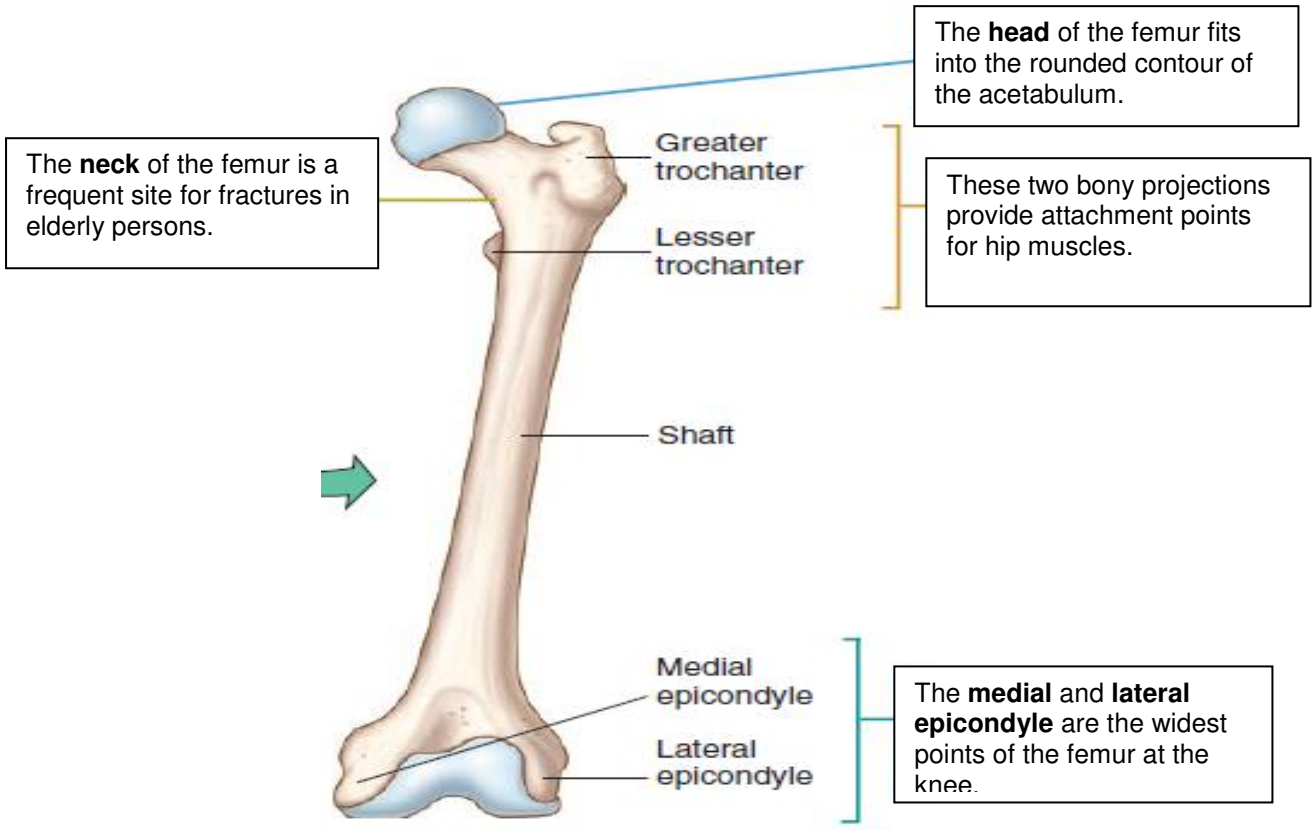

Commonly known as the kneecap, the **patella** is a triangular sesamoid bone embedded in the tendon of the knee. At birth, the patella is composed of cartilage. It ossifies between the ages of three and six years.



Fibula

The long and slender **fibula** resides alongside the tibia and helps stabilize the ankle.

It does not bear any weight.

Tibia

Of the two bones in the lower leg, the **tibia** is the only one that bears weight.

Commonly called the shinbone, the tibia articulates with the femur.

Foot and Ankle

The bones of the foot and ankle are arranged similarly to those of the hand. However, because the foot and ankle bear the weight of the body, the size of the bones, as well as how they're arranged, differs.

The **phalanges** form the toes. The great toe, called the **hallux**, contains only two bones: a proximal and distal phalanx. The remaining toes contain a proximal, middle, and distal phalanx.

The **metatarsals**—which are numbered I through V, beginning medially—form the middle portion of the foot.

Navicular

The **tarsal bones** comprise the ankle.

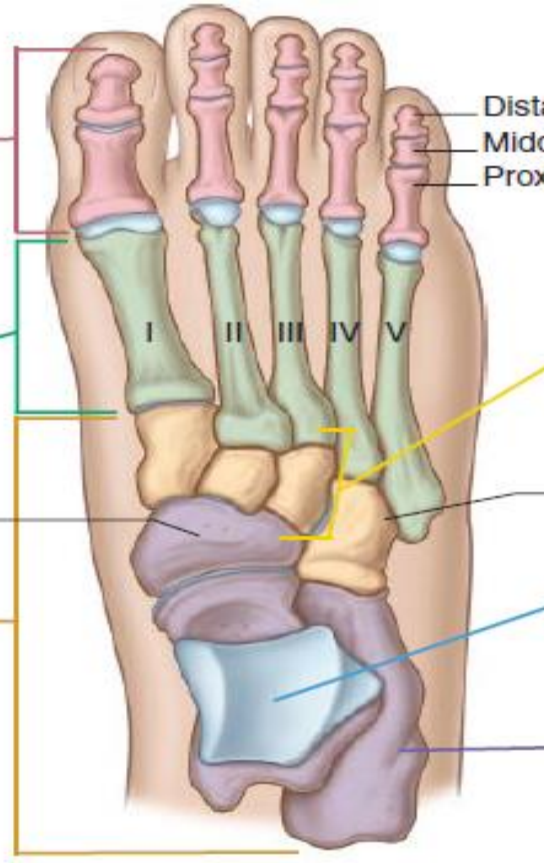

The distal row of tarsal bones consists of three **cuneiforms** and the large **cuboid**.

The second-largest tarsal bone is the **talus**.
The talus articulates with three bones: the calcaneus on its inferior surface, the tibia on its superior surface, and another tarsal bone (called the **navicular**) on its anterior surface.

The largest tarsal bone is the **calcaneus**.
This bone, which forms the heel, bears much of the body's weight

Arches of the Foot

Strong ligaments hold the foot bones together in a way that forms arches in the foot. Just as arches add supporting strength to a building, foot arches give the foot more strength to support the weight of the body.

