Anatomy

Lecture 6

Joints

Joints—also called **articulations**—are points where bones meet. Some joints are completely immovable; others allow only limited movement. Most joints, however, permit considerable movement. Through the interaction of multiple interconnecting parts, these incredible structures allow the body to walk, run, dance, throw a ball, and even type on a computer.

Joints may be classified according to how movable they are: fixed, semi-movable, or freely movable. They may also be classified according to the material that binds them together. For example, fixed joints are bound by fibers and are called fibrous joints; semi-movable joints are joined by cartilage and are called cartilaginous joints; freely movable joints contain a fluid-filled joint capsule and are called synovial joints.

Fibrous Joints

Fibrous joints—also called **synarthroses**—result when collagen fibers from one bone penetrate the adjacent bone, anchoring the bones in place.

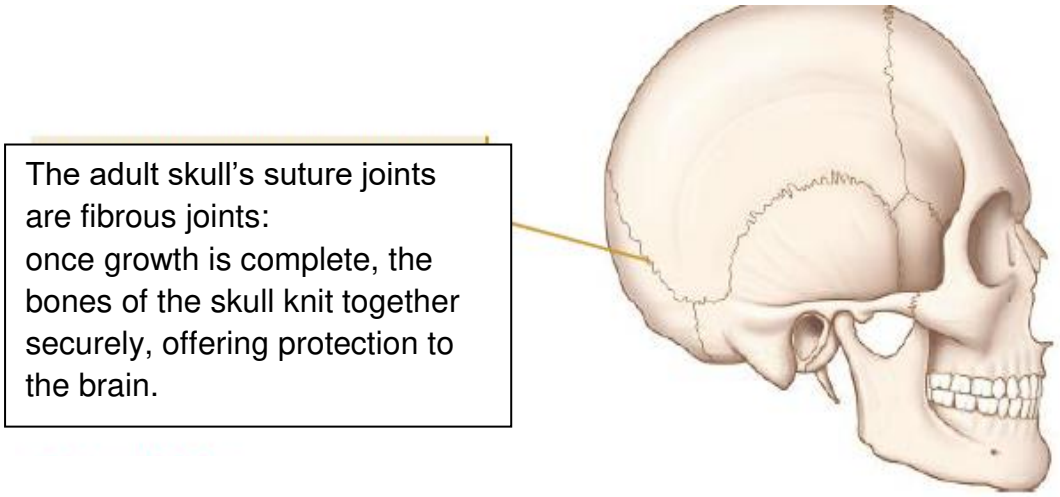

Cartilaginous Joints

In **cartilaginous joints**, two bones are joined by cartilage. These joints—called **amphiarthroses**—are slightly movable.

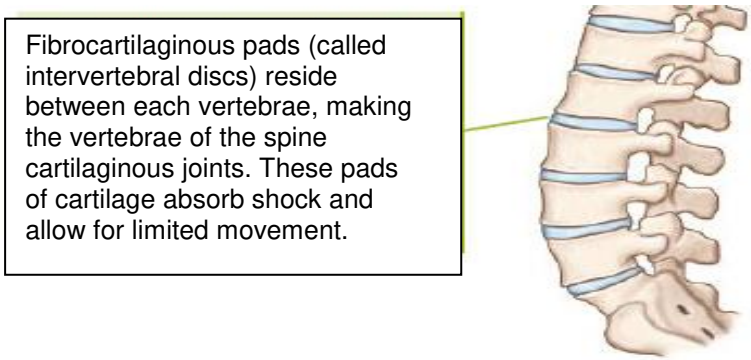

Synovial Joints

Synovial joints—also called **diarthroses**—are freely movable. They're also the most numerous and versatile of all the body's joints. Every synovial joint contains the following structures:

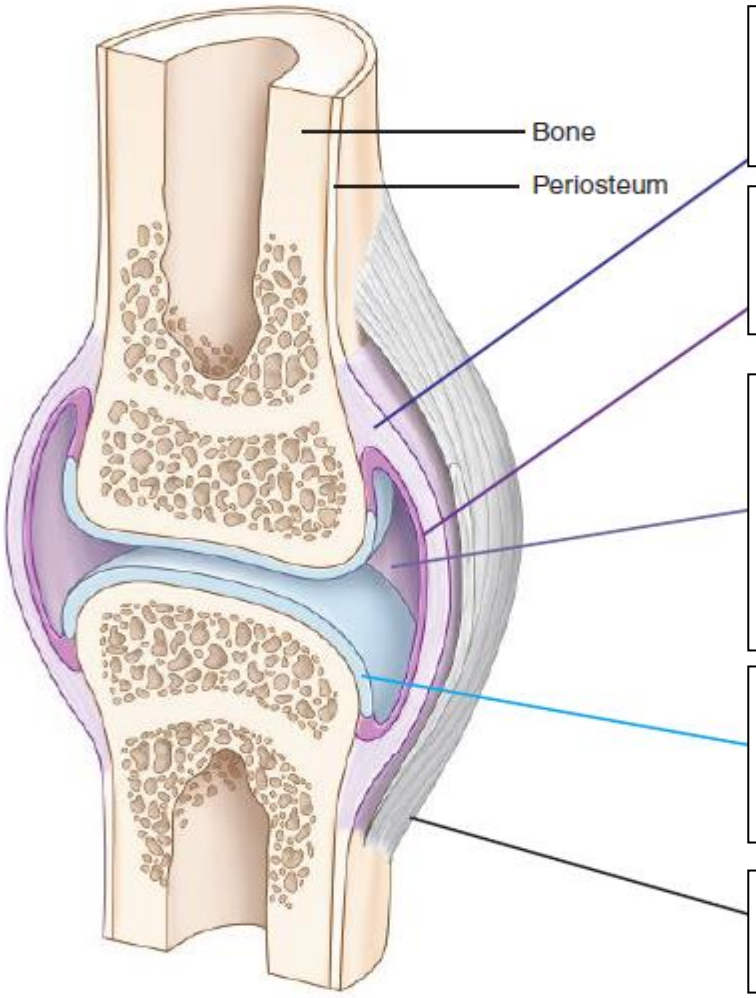

Joint capsule: is a sheet of connective tissue that encloses the joint cavity.

Synovial membrane: This moist, slippery membrane lines the inside of the joint capsule, where it secretes synovial fluid.

Joint cavity: This small space between the bones allows for freedom of movement. It also contains **synovial fluid**, a slippery, viscous fluid that has the consistency of an egg white. Synovial fluid lubricates the joint, nourishes the cartilage, and contains phagocytes to remove debris

Articular cartilage: A thin layer of hyaline cartilage covers the bone surfaces. In combination with synovial fluid, the articular cartilage permits friction-free movement.

Ligaments: Tough cords of connective tissue help bind the bones more firmly together.

Bursae in Synovial Joints

Some joints—such as the knee, shoulder, and elbow—contain small sacs filled with synovial fluid called **bursa** (plural: **bursae**). Residing in areas where muscles and tendons pass over bony prominences, the bursae facilitate movement and ease friction.

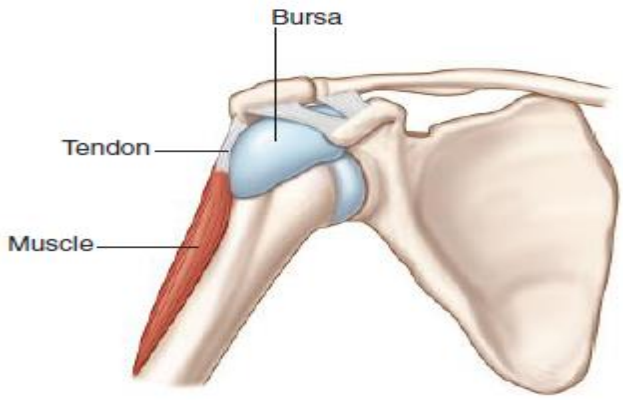

Movements of Synovial Joints

The movements a joint can make depend upon the shape of the joint (as previously discussed) as well as the involvement of nearby muscles, tendons, and ligaments.

Flexion and Extension



Flexion



Extension

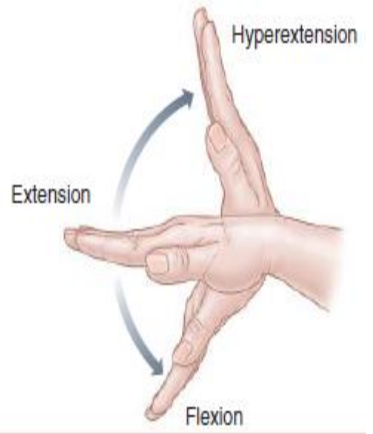

Hyperextension



Dorsiflexion



Plantar flexion

Abduction and Adduction



Abduction



Adduction



Circumduction



Internal rotation



External rotation

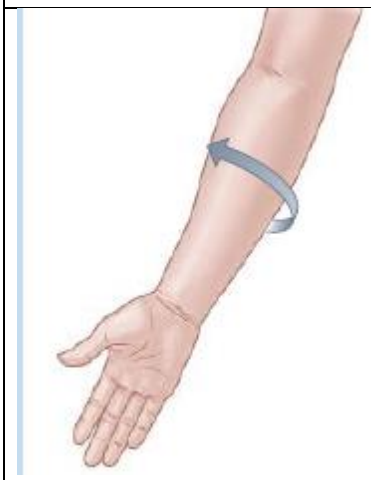

Supination



Inversion

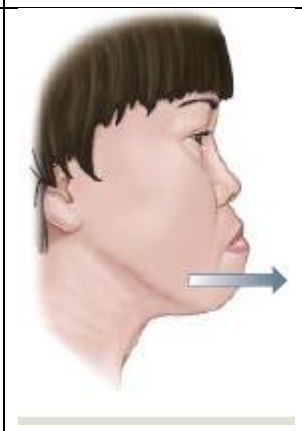

Protraction



Pronation



Eversion



Retraction

MUSCULAR SYSTEM

Muscles are a unique form of tissue that transform energy into motion. Everything your mind conceives is transmitted to your muscles to perform. The words you speak, the expression on your face, the motion of your fingers as you write or play an instrument are possible only because of muscular movement. Even more, muscles operate behind the scenes to propel blood through blood vessels, drive the flow of air into and out of the lungs, digest food, and produce body heat. Indeed, this sophisticated tissue helps sustain life.

The body contains three types of muscle: cardiac muscle, smooth muscle, and skeletal muscle.

Cardiac Muscle • Found only in the heart • Consists of short, branching fibers that fit together at **intercalated discs** • Appears striped, or **striated**, when viewed under a microscope • Is a type of **involuntary** muscle because it contracts automatically	
Smooth Muscle • Found in the digestive tract, blood vessels, bladder, airways, and uterus • Does not appear striped when viewed under a microscope, so is called **nonstriated** • Known as involuntary muscle, because it contracts automatically (such as when the digestive tract processes food)	
Skeletal Muscle • Attached to bone and causes movement of the body • Known as **voluntary** muscle because it can be contracted at will • Appears markedly striated when examined with a microscope	

Muscles of the Head and Neck

Muscles in this region are typically grouped according to their function: muscles of facial expression, muscles of chewing (called mastication) and swallowing, and muscles that move the head.

Of all the muscles of the face, the area around the mouth is the most complex. This makes sense considering that the mouth is the most expressive part of the face; the movement of the lips is also pivotal in the formation of words. Besides contributing to facial expression, the muscles of the face allow us to speak, chew, and perform other oral functions.

Muscles of Facial Expression

1. **Frontalis**
2. **Orbicularis oculi**
3. **Zygomaticus**
4. **Orbicularis oris**

Muscles of Chewing

Temporalis

Masseter

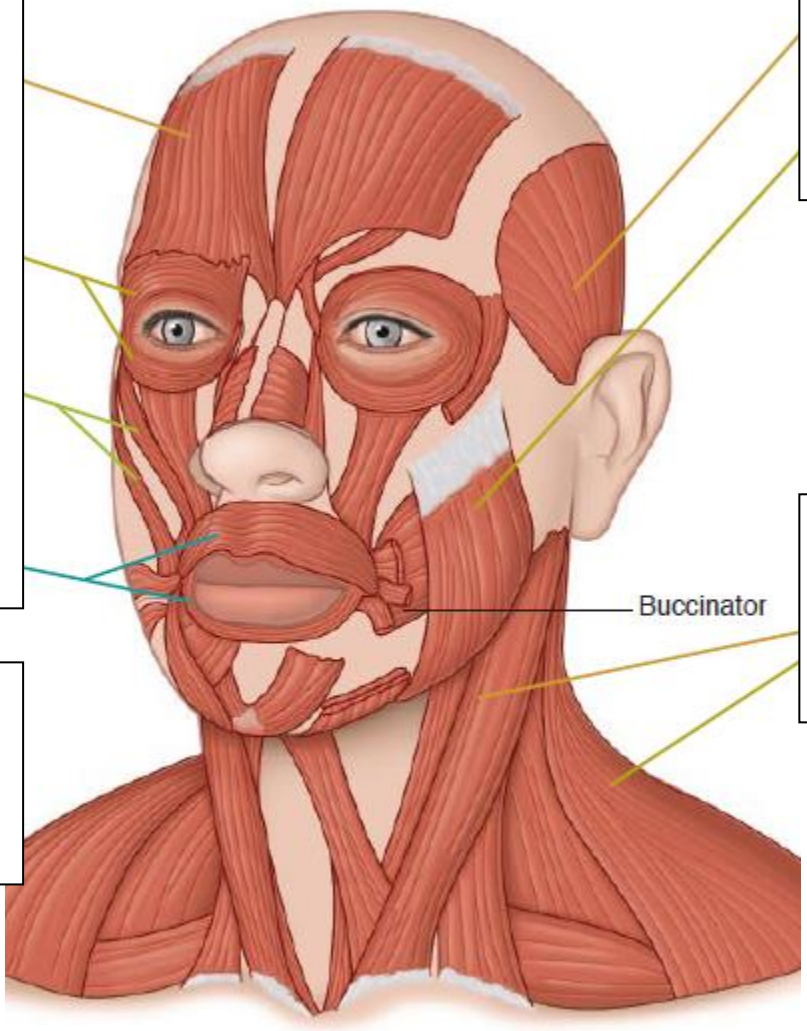

Muscles That Move The Head

1.Sternocleidomastod

2.Trapezius

Buccinator (shown on the other side of the face):
Assists in smiling and blowing

Muscles Involved in Breathing

Muscles are the driving force behind our ability to breathe

External intercostals

Internal intercostals

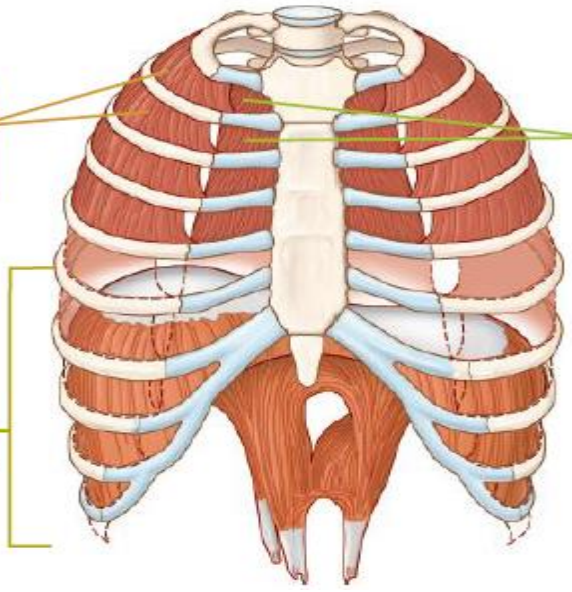

Diaphragm

Muscles Forming the Abdominal Wall

abdominal wall derives its strength from alternating layers of muscle. The muscle fibers in each of the three layers forming the abdominal wall run in different directions

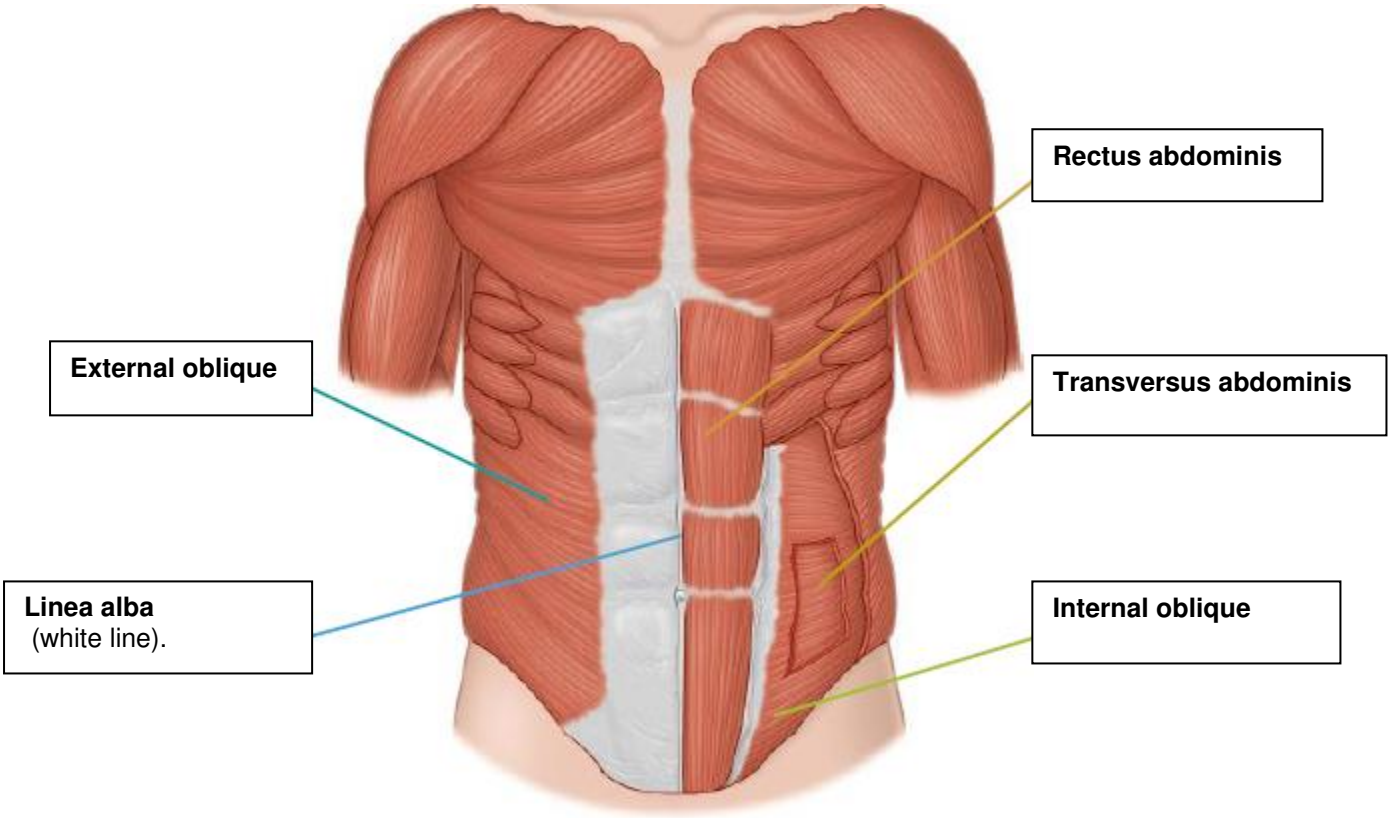

Muscles of the Shoulder and Upper Arm

The shoulder and upper arm perform a wide variety of movements. Some movements—such as throwing a ball or swimming—require power and a full range of motion. Others, such as writing, depend upon more subtle movements. To make these motions possible, the shoulder draws on a complex variety of muscles. A few of those muscles are illustrated in the figure below.

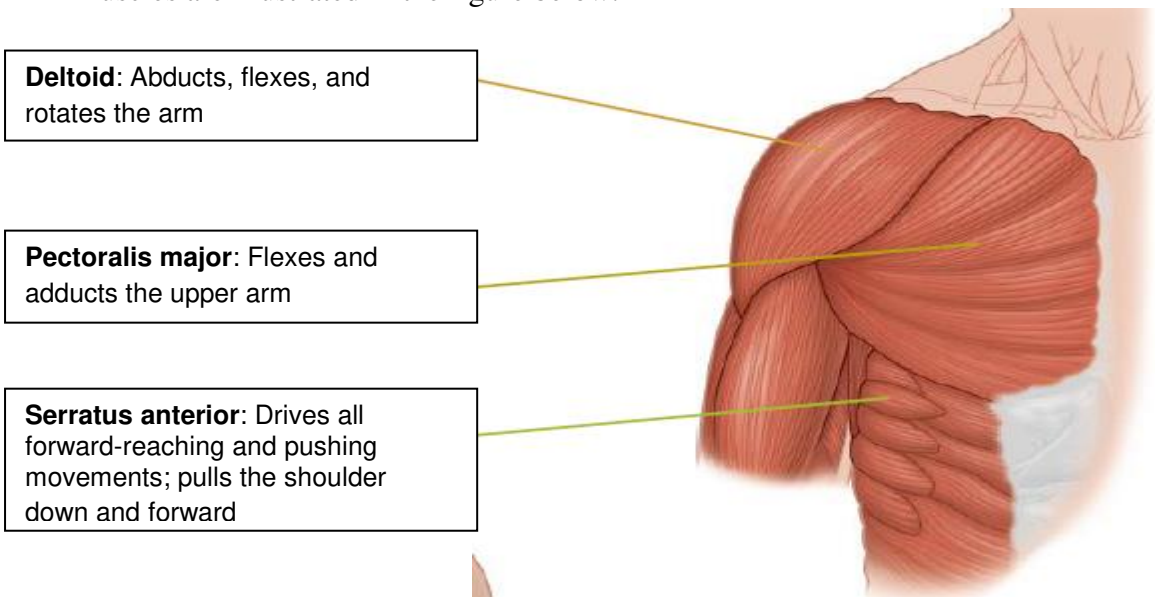

Trapezius: Raises and lowers the shoulders; stabilizes the scapula during arm movements

Latissimus dorsi: Adducts the humerus; extends the upper arm backward

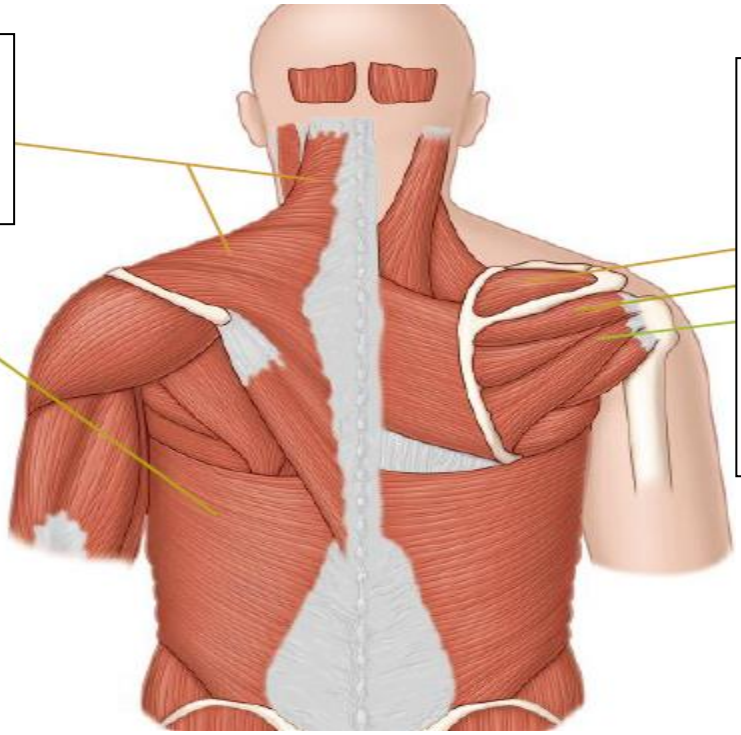

Rotator cuff: The tendons of four muscles (attached to the scapula) form the rotator cuff. They are the:

- **supraspinatus**
- **infraspinatus**
- **teres minor** and
- **subscapularis** (on the anterior scapula)

Muscles That Move the Forearm

The muscles that flex and extend the forearm are located on the humerus.

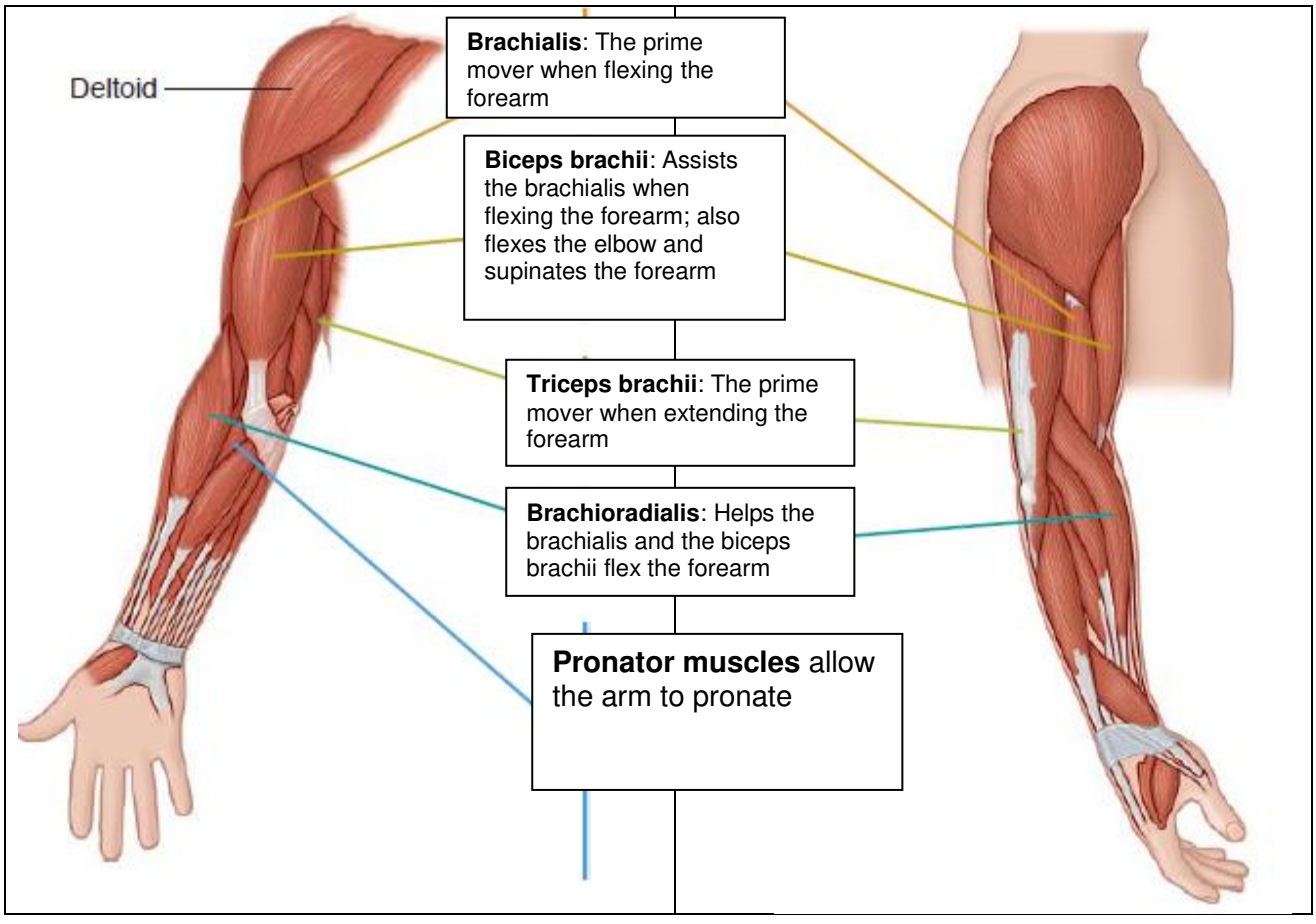

Muscles Acting on the Hip and Thigh

the legs are built for stability and power. The muscles of the hip and thigh enable the body to stand, walk, and maintain balance.

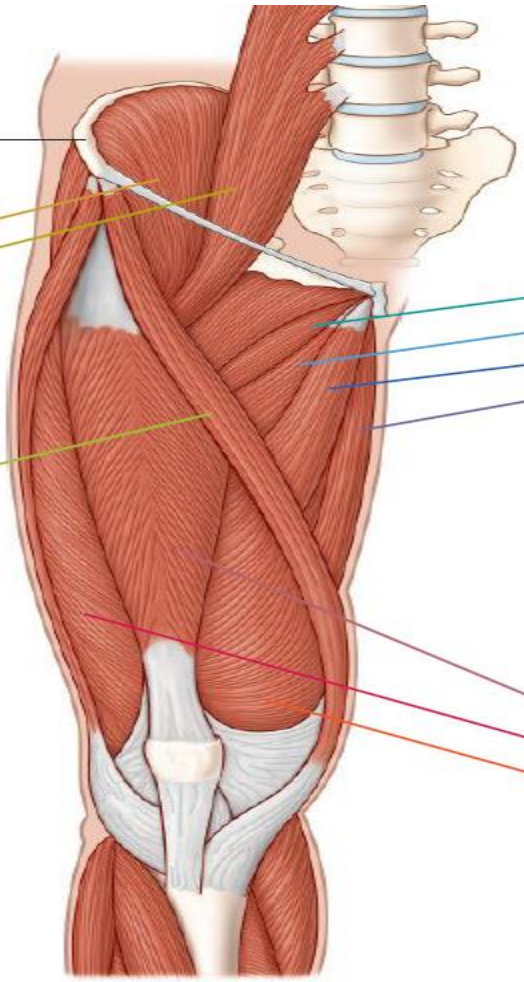

The **iliopsoas** flexes the thigh
The term iliopsoas refers to a combination of the following muscles:
- **Iliacus**
- **Psoas major**

The **sartorius** is the longest muscle in the body. It aids in flexion of the hip and knee (such as when sitting) and abducts and laterally rotates the thigh

The **adductor muscles** rotate and draw the thigh in toward the body (adduction).
This group consists of the following muscles:

- **Adductor magnus**
- **Adductor brevis**
- **Adductor longus**
- **Gracilis**

The **quadriceps femoris**—the most powerful muscle in the body—is the prime mover for knee extension. It consists of four muscles, although only three are visible here. The fourth, the **vastus intermedius**, lies underneath the rectus femoris.
- **Rectus femoris**
- **Vastus lateralis**
- **Vastus medialis**

The gluteal muscles consist of the following three muscles:
Gluteus medius: Abducts and rotates the thigh outward
Gluteus maximus: The bulkiest muscle in the body; it produces the backswing of the leg when walking and provides most of the power for climbing stairs
Gluteus minimus: This muscle lies beneath the other two gluteal muscles

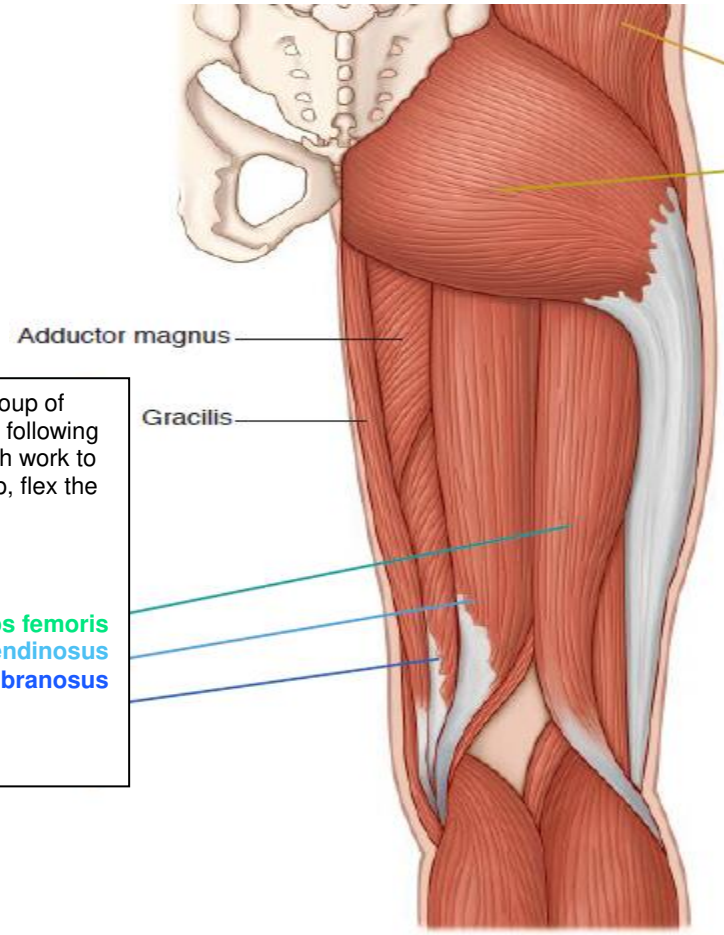

The **hamstrings** are a group of muscles consisting of the following three muscles, all of which work to extend the thigh at the hip, flex the knee, and rotate the leg.

Biceps femoris
Semitendinosus
Semimembranosus

Muscles Acting on the Foot

Muscles in the lower leg are primarily responsible for moving the foot and ankle.



Gastrocnemius

Soleus
Contraction of these muscles causes plantar flexion of the foot

calcaneal (Achilles) tendon.
It inserts on the calcaneus (heel bone).

Muscles on the anterior of the lower leg also participate in moving the foot and ankle.

The extensor digitorum longus and the tibialis anterior dorsiflex the foot, keeping the toes from dragging the ground when walking. The extensor digitorum longus also extends the toes and turns the foot outward (eversion).

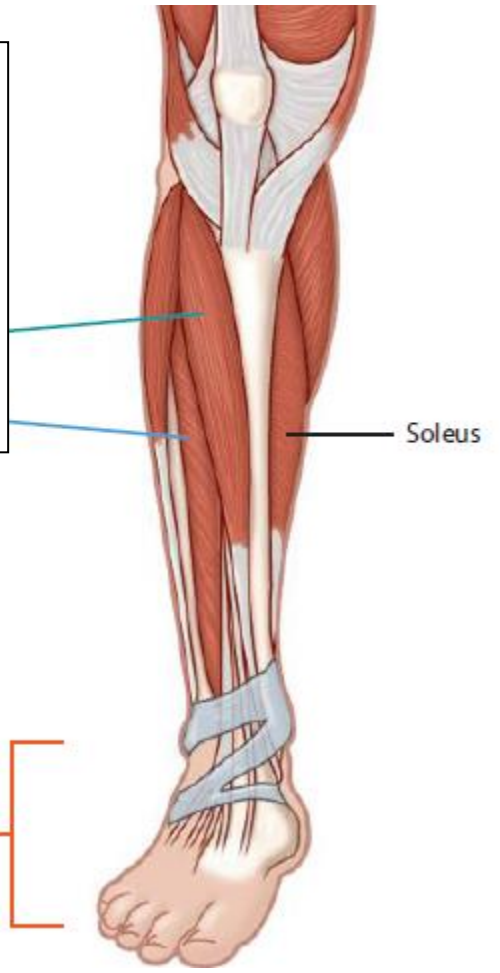

The muscles of the lower leg pull on tendons that attach to the bones of the foot. The foot also contains numerous smaller muscles that act to flex and extend the toes.