وزارة التعليم العالي والبحث العلمي

كلية الحله الجامعه الاهليه

قسم الفيزياء الطبيه

Morphological study of liver in mice

A Graduation Project Is Submitted to the Al-Ahlia University in Partial Fulfillment of the Requirements for the Degree of Bachelor of Science in Department of Medical physics sciences

By B.Sc. Students

Kadhim Mohammed Kadhim

Muthana Kareem Jassim

Muhammad Jassim Suleiman

Supervised by A.Lec. Ousama murtadha

Iraq Babylon,

2023-2024



قُلْ هَلْ يَسْتَوِي الَّذِينَ يَعْلَمُونَ وَالَّذِينَ لاَ

يَعْلَمُونَ إِنَّمَا يَتَذَكَّرُ أُولُو الأَلْبَابِ



سورة الزمر (الآية 9)

DEDICATION

I dedicate this work

To… my family, my project supervisor, the people

who I love, Friends

And

Everyone who believes in me.

"Thanks for supporting"

Supervisor's Certificate

I certify that this thesis entitled "" has been prepared under my supervision at Medical physics sciences Department, Al- Hilla University College - Iraq, as a partial fulfillment of the requirements for the degree of Bachelor of Science in Medical physics sciences

Signature

Supervisor Name

Date / /2024

Acknowledgments

(In The Name of Allah, the Gracious, the Merciful)

(Thanks to Allah for his guidance and help)

I wish to express my deep gratitude to my supervisor for his Invaluable help, advice and encouragement during the various Stages of the present work.

My grateful acknowledgment is due to My father andMy mother for their assistance and patience.

Finally, I record my sincere gratitude to all those who have Helped me throughout this research even by a one word.

Students Names

2024

Table of Content

Table of Contents

Chapter One 1

1.1 **Overview** 1

1.2 The problem statements 2

1.3 The Main Goals of Project 2

1.4 Outlines 3

Chapter Two 4

2.1 Introduction 4

2.2 Mouse models for liver cancer 4

2.2.1 Molecular oncology 5

2.2.2 HCC 6

2.2.3 Conventional mouse models for liver cancer development 7

2.2.4 Application of chimeric mice 8

2.3 characteristics of PXB-mice 9

Chapter Three 13

3.1 Introduction 13

3.2 Breeding of the uPA-SCID Mice 13

3.2.1 .isolation of human hepatocytes and transfer into uPA-SCIDMic 13

3.2.2 Quantification of Human Albumin 14

3.2.3 Detection and Quantification of Viral DNA/RNA and Proteins……14

3.2.4 Detection of Human Proteins in Chimeric Plasma 14

3.2.5 uPA-SCID Mouse Livers Used for Histopathological Evaluation 15

Chapter Four 16

4.1 Introduction 17

4.2 Plasma Analysis of Chimeric Mice 17

4.2.1 Histological Studies of Uninfected Chimeric Livers Chimeric uPA-SCID Mice 36 and 78 Days After Transplantation 18

4.3Discussion 20

Chapter Five 21

5.1 Introduction 22

5.2 Conclusion 22

References 23

Table of Figure

Figure 2.1 Mouse models to study HCC development 6

Figure 2.2 chimeric PXB-mice 9

Figure 2.3 approximately 30 weeks old 10

Figure 2.4 Mice liver 11

Figure 2.5 HBV&HCV 11

Figure 4.1 human albumin concentrations 17

Figure 4.2 mature human hepatocytes were identified in the livers..... 18

Figure 4.3 Histology of a chimeric liver 19

Abstract

The nb/nb mouse with a hereditary hemolytic anemia is an animal model of hemolysis-induced gallstone disease. These anemic mice have hepatomegaly and form calcium bilirubinate gallstones. We undertook this study to: (a) examine the histopathology of the liver and gallbladder in nb/nb mice and (b) assess the influence of hemolysis per se on liver and gallbladder histology by transplanting nb/nb bone marrow into another genotype W/Wv. Livers and gallbladders obtained from male nb/nb and control mice of similar age were stained with hematoxylin and eosin. Gallbladders were also stained with alcian blue (pH 2) and periodic acid-Schiff for acidic and neutral glycoproteins, respectively. Volume densities of the extralobular (blood vessels) and lobular (hepatocytic and sinusoidal) components of the liver and glands of the gallbladder neck were determined by standard morphometric techniques.[1]

Chapter One

Introduction

Chapter One

1.1 Overview

The liver mass of nb/nb mice was 25% greater than that of control mice (1.79 ± 0.26 S.D. gm vs. 1.43 ± 0.23, $p < 0.001$). The actual hepatocytic mass of nb/nb and control mice was similar (1.35 ± 0.19 gm vs. 1.26 ± 0.21, $p > 0.05$). However, the sinusoidal compartment, representing extramedullary hematopoiesis, was three times greater in nb/nb than in control livers (0.40 ± 0.13 gm vs. 0.13 ± 0.05, $p < 0.001$). Overall, glandular concretions within the gallbladders were present at least twice as often in nb/nb than in control mice ($p < 0.02$). Bile pigment concretions occurred in only nb/nb gallbladders and were present three times more frequently in those with luminal gallstones (81%) than in those without stones (25%) ($p < 0.02$). [2].

These data indicate that: (a) the hepatomegaly of nb/nb mice is due to extramedullary hematopoiesis while the morphological mass of hepatocytes is similar in control and nb/nb mice; (b) bile pigment concretions within nb/nb gallbladders precede luminal calcium bilirubinate stone formation; (c) glandular hyperplasia is a secondary event in hemolysis-induced gallstone disease, and (d) the hemolytic anemia is responsible for the hepatomegaly and gallstone formation, but the genotype determines the glandular density and concretions within the gallbladder prior to luminal gallstone formation. [3].

The metastatic capabilities of well-defined nodular hepatic lesions induced by benzo(a)pyrene, ethylnitrosourea, benzidine · 2HCl, and diethyInitrosamine were evaluated. Coded liver and lung tissues from 1264 treated C57BL/6J × C3HeB/FeJ F1 mice were assessed independently for the presence of primary nodular lesions and metastases, respectively. Primary lesions were classified according to their size, cell morphology, and growth

patterns into hyperplastic, adenomatous, and trabecular nodules. None of the 126 mice bearing hyperplastic nodules had pulmonary metastases. Four of 291 (1.4%) mice with adenomatous nodular lesions showed metastases. In contrast, of the 733 mice bearing the trabecular type of nodular lesions alone or in combination with other lesions 266 (36%) showed pulmonary metastases. The pulmonary metastases were first detected in mice dying between 51 and 60 weeks of age (5%). This rate increased as a function of age at death, reaching an incidence of 51% in mice surviving more than 81 weeks. It was concluded that nodules showing trabecular and the more anaplastic solid sheet type of growths represented bona fide hepatocellular carcinomas in the mouse. [4].

The histogenesis of trabecular hepatocellular carcinomas was studied in male B6C3 F1 mice that were given injections of 5 micrograms diethylnitrosamine (DENA)/g body wt when they were 15 days old. Fully developed trabecular carcinomas with characteristically thickened hepatic plates were not seen until 44 weeks after DENA injection. However, focal microscopic collections of RNA-rich hepatocytes, referred to as basophilic hepatic foci, were first noted at 10 weeks after DENA injection. [5].

1.2 The problem statements

According to the World Health Organization, It is estimated that 58 million people are chronically infected with hepatitis C virus globally, with 1.5 million new infections recorded each year. Hence it is a way to prevent or help reduce losses in people's lives.

1.3 The Main Goals of Project

The goal of this project is to Experimental mice are among the most important research methods that take place before the use of any medicine for humans.

1.4 Outlines

In addition to what explained above, this research will show the theory part in chapter two and chapter three, the result and experiments in chapter four, finally this research will finish with conclusion and future works.

Chapter Two

Theory Part

Chapter Two

2.1 Introduction

The previous chapter discusses an overview of the research, the problems that can be solved with it, a brief description of similar research, and finally its main goal.

In this chapter, we will discuss what was used to build and achieve this research through previous studies and research.

2.2 Mouse models for liver cancer

Hepatocellular carcinoma (HCC), the most common form of primary liver cancer is the third leading cause of cancer-related cell death in human and the fifth in women worldwide. The incidence of HCC is increasing despite progress in identifying risk factors, understanding disease etiology and developing anti-viral strategies. Therapeutic options are limited and survival after diagnosis is poor. Therefore, better preventive, diagnostic and therapeutic tools are urgently needed, in particular given the increased contribution from systemic metabolic disease to HCC incidence worldwide. In the last three decades, technological advances have facilitated the generation of genetically engineered mouse models (GEMMs) to mimic the alterations frequently observed in human cancers or to conduct intervention studies and assess the relevance of candidate gene networks in tumor establishment, progression and maintenance. Because these studies allow molecular and cellular manipulations impossible to perform in patients, GEMMs have improved our understanding of this complex disease and represent a source of great potential for mechanism-based therapy development. In this review, we provide an overview of the current state of HCC modeling in the mouse, highlighting successes, current challenges and future opportunities. [6] .

2.2.1 Molecular oncology

Chronic HBV or HCV infections currently account for more than 80% of HCC, the best strategy to prevent HCC is to eradicate viral infections. A vaccine against HBV has been developed in 1982 and is routinely used in many countries.

Vaccination has reduced persistent HBV infections and led to marked reduction in hepatitis B-related liver cancer (Romano et al., 2011). However, the millions of adults, who were infected before universal vaccination or that cannot afford it, are still at risk of developing HCC and the emergence of vaccine-resistant hepatitis B surface antigen mutants is a serious concern. Hepatitis C-associated cirrhosis is the leading cause of liver transplantation and despite encouraging results, no vaccine can currently protect against HCV infection (Feinstone et al., 2012). Fortunately, a treatment is available

and effective in 50e80% of patients with persistent HCV infection, and better treatments are in sight (Dore, 2012). However, therapeutic options remain costly and patients with advanced liver pathologies will continue to require expensive disease

management. [7].

2.2.2 HCC

HCC is expected to rise, further increasing the burden of liver diseases in years to come (Baffy et al., 2012).

Understanding the cellular and molecular mechanisms leading to HCC, and most importantly those which are connected to systemic/ metabolic influences has therefore become an urgent and imperative issue.

Without this knowledge, developing efficient preventive, diagnostic a therapeutic countermeasures is bound to fail. [8] .

Table 1 – Mouse models to study HCC development.

	Properties	Latency	Notes
Chemical			
DEN/Phenobarbital DEN (single injection)	Genotoxic	5–10 m	When DEN is injected to adults promotion is needed, used in combination with genetic/dietary/environmental models
Aflatoxin	Genotoxic	>22 m	Often combined with genetic models
CDE diet, TAA, CCl4, peroxisome proliferators etc.	Associated with steatohepatitis, fibrosis, etc.	>12 m	Variability due to different experimental protocols, used for context-specific modeling. Often combined with DEN or genetic models
GEMMs			
HBV-derived (sAg, HBx)	ER stress,focal necrosis, proliferation	12–24 m	Several lines/backgrounds with different penetrance/latency
HCV-derived (Core)	Steatosis	12–24 m	Several lines/backgrounds with different penetrance/latency
Mdr2 knock-out	Cholangitis	>12 m	Strong inflammatory component, strain dependent
Mosaic GEMMs			
Somatic gene/molecules delivery: Virus-based, RCAs/TVA, Hydrodynamic	Fast, cost-effective	Few weeks	Can be combined with GEMMs, suitable for imaging
Implantation models: p53KO; mycTg hepatoblasts	Fast, cost-effective	Few weeks	Suitable for imaging and large-scale screens

More examples and details can be found in Newell et al., 2008; Li et al., 2011.

Figure 2.1 Mouse models to study HCC development

2.2.3 Conventional mouse models for liver cancer development

Inbred strains of mice differ greatly in their susceptibilities to spontaneous liver tumors (Drinkwater, 1988).

This inter-strain variation of wild-type mice represents a valuable resource and is still used to identify liver tumor susceptibility genes (Peychal et al., 2009). Early on, efforts were made to develop better models, where tumors would develop more rapidly, with high penetrance and synchronous kinetics.

The pathogenic alterations causing liver cancer were originally modeled through the use of chemicals or by classical transgenic approaches, where genes regarded as potentially relevant for liver cancer were introduced in the mouse genome. These early efforts were often assisted by serendipitous discoveries and unexpected findings. [9] .

2.2.4 Application of chimeric mice

We have succeeded in stable mass production of chimeric PXB-mice, whose liver is repopulated by human hepatocytes at a ratio of more than 70%, and we are providing these mice to academia and pharmaceutical companies to support the development of new drugs or studies of liver function. Furthermore, we isolated human hepatocytes, called PXB-cells, from the chimeric mice, and provide them for clients weekly for in vitro studies. In this review, we summarize the existing characterizations of PXB-mice and PXB-cells and their present and future applications. [10] .

2.3 Characteristics of PXB-mice

Cryopreserved human hepatocytes (1–10 × 105 cells) were transplanted into 2–4-week-old hemizygous cDNA-uPA/SCID mice via spleen. Transplanted human hepatocytes engrafted and grew in the host mouse liver, and at 2 months after transplantation we obtained chimeric PXB-mice (Fig.2.2). Blood human albumin (h-alb) levels and body weight gradually increased in the hemizygous cDNA-uPA/SCID mice and then were maintained until they were approximately 30 weeks old (Fig.2.3). h-Alb levels in mouse blood were well correlated with human hepatocyte RI of the mouse liver (Fig.2.4). H&E stained sections of hemizygote cDNA-uPA/SCID chimeric mouse livers showed that area most occupied with human hepatocytes had clear cytoplasm, and various-sized mouse hepatocytes with eosinophilic cytoplasm were observed (Fig.2.5). The RI was calculated as the ratio of the area occupied by human cytokeratin 8/18 (hCK8/18)-positive human hepatocytes to the entire area examined on immunohistochemical sections from seven lobes of the liver . [11].

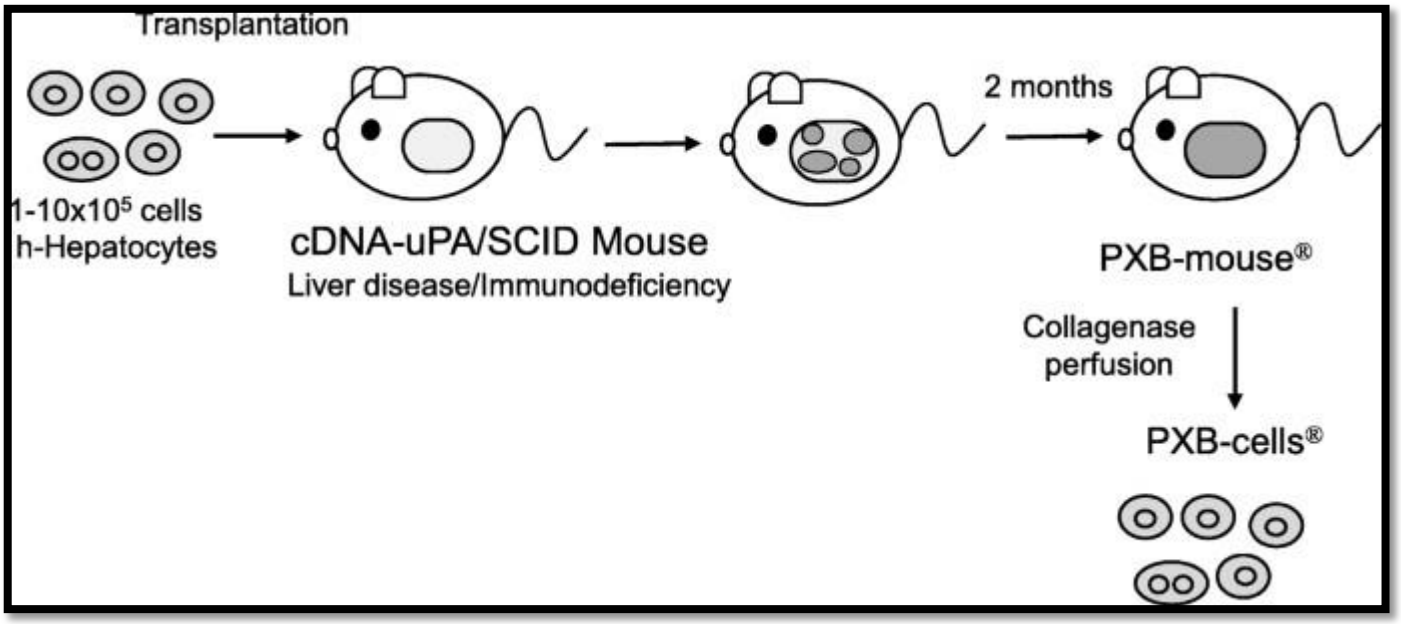

Figure 2.2 chimeric PXB-mice

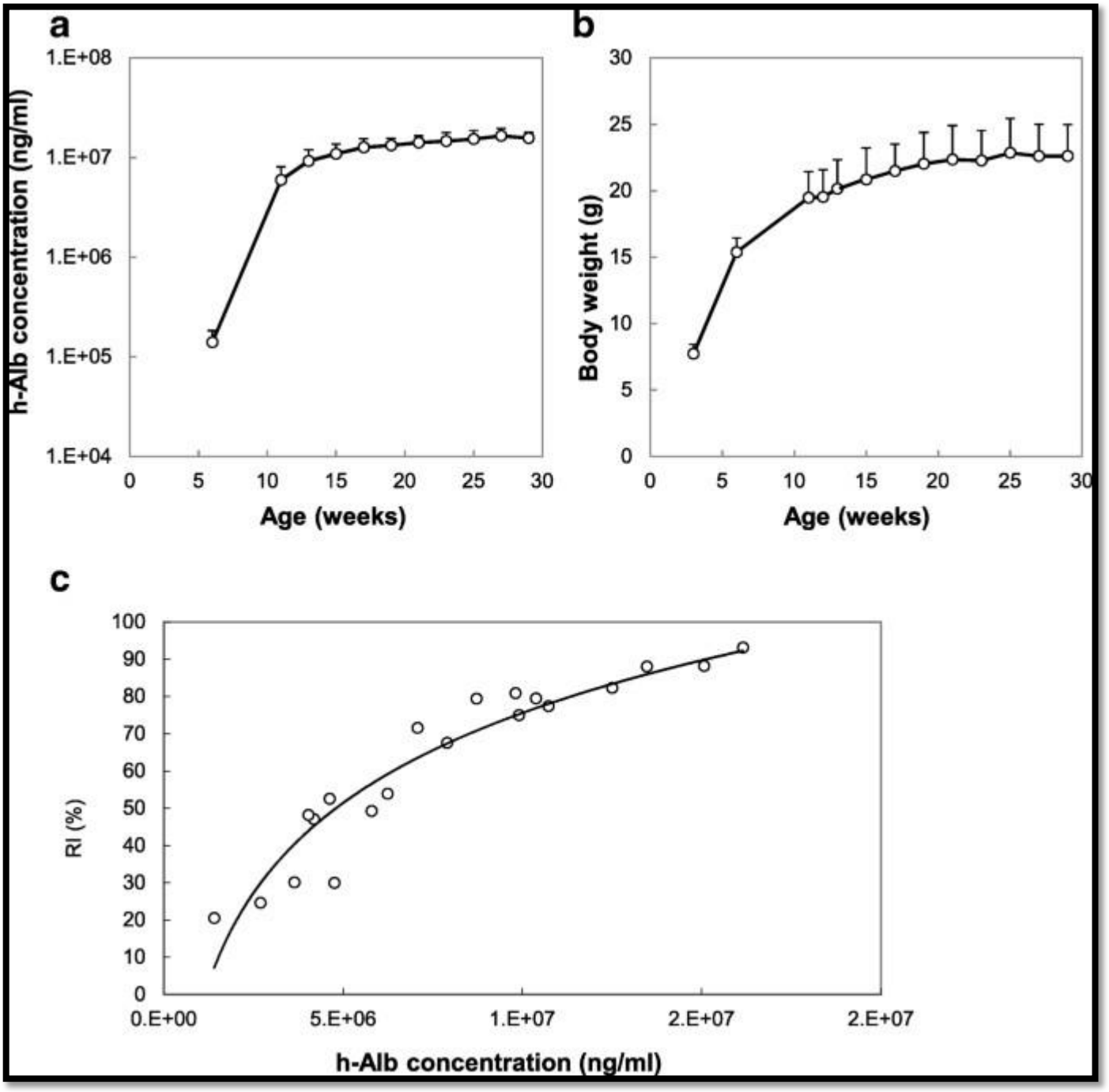

Figure 2.3 approximately 30 weeks old

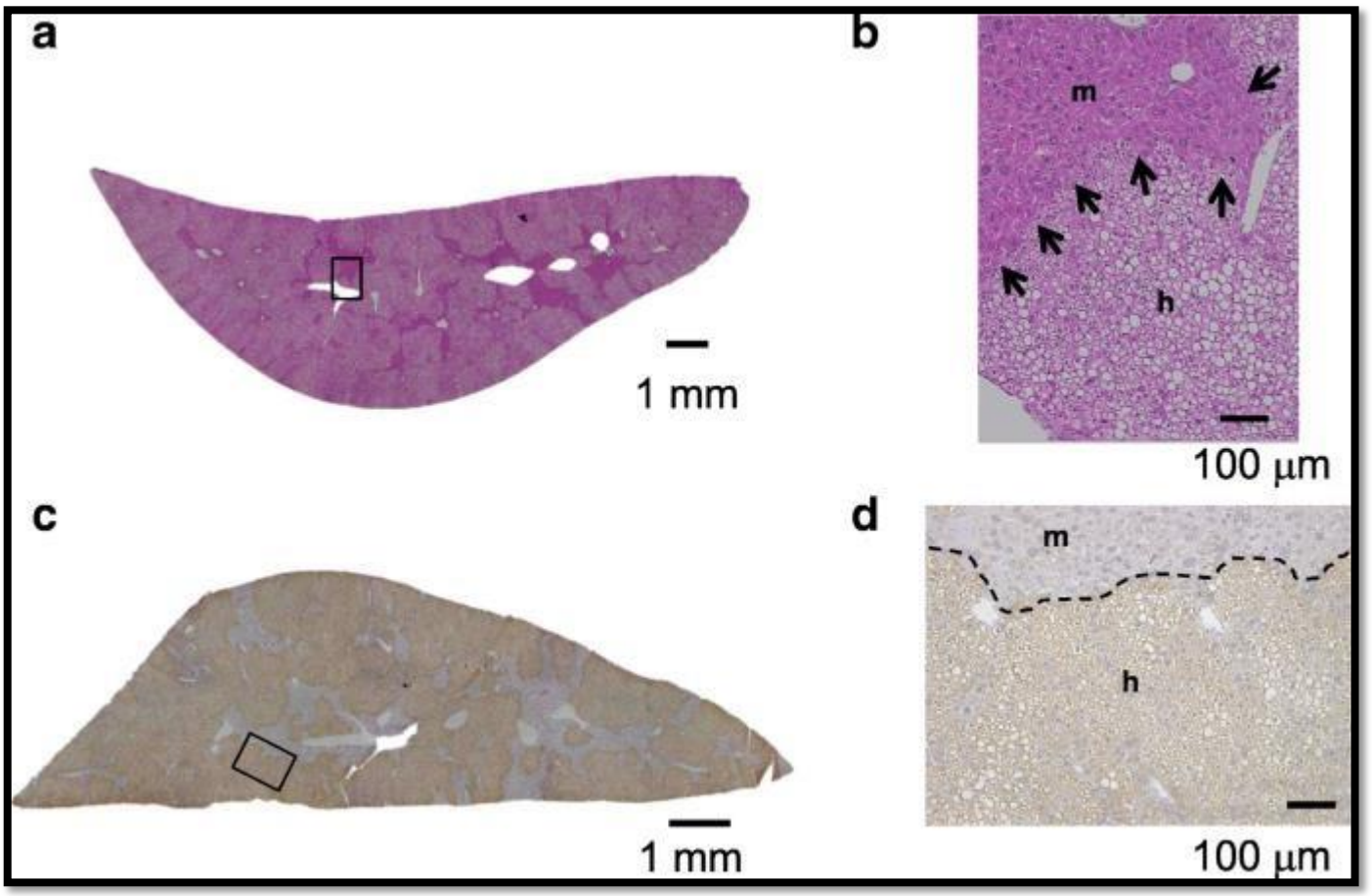

Figure 2.4 Mice liver

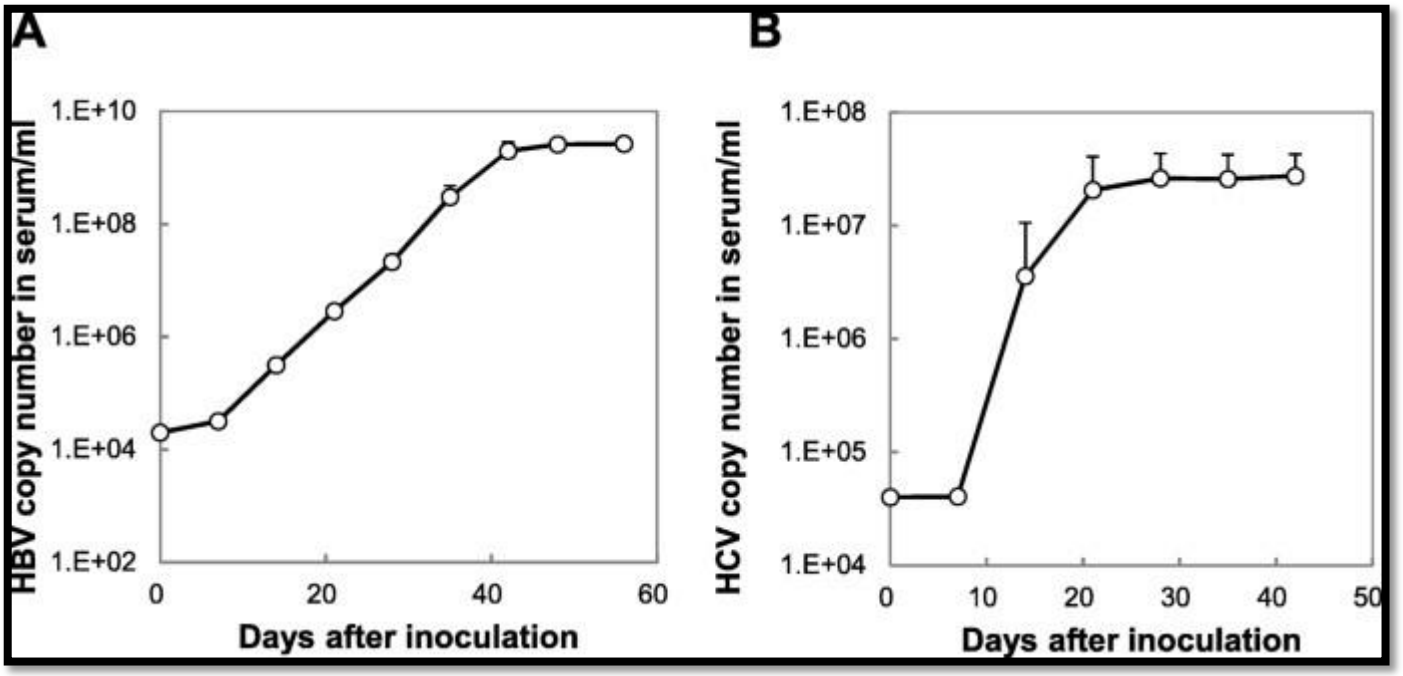

Figure 2.5 HBV&HCV

Chapter Three

Materials and Methods

Chapter Three

3.1 Introduction

The previous chapter provided an overview of mouse livers, hepatocellular carcinoma, and all the tools and environments used to implement the proposed approach. This chapter provides an overview of the proposed system approach that provides an efficient approach to resource allocation and also describes the design of the proposed system in detail. A brief description of the steps of the research method and system will be included in this chapter.

3.2 Breeding of the uPA-SCID Mice

B6SJL-TgN(Alb1Plau)144Bri mice were, at least 7 times, back-crossed on CBySmn.CB17-Prkdcscid mice. Both strains were purchased from The Jackson Laboratories (Bar Harbor, ME). Screening for the SCID background was done with an in-house mouse immunoglobulin M (IgM) sandwich ELISA. Genotyping of the uPA-SCID mice was performed via a multiplex polymerase chain reaction as described before.9 Human hepatocytes were transferred only in animals homozygous for the uPA-transgene. The study protocol was approved by the Animal Ethics Committee of the Faculty of Medicine of the Ghent University.[12] .

3.2.1 Isolation of Human Hepatocytes and Transfer into uPA-SCID Mice

Human liver specimens were collected from patients undergoing a partial hepatectomy for the resection of metastatic disease. All patients gave written, informed consent, and all experiments were approved by the Ethical Committee of the Ghent University Hospital. Hepatocytes were isolated from tumor-free sections via a collagenase digestion. Briefly, tissue was first perfused with Liver Perfusion Medium (Invitrogen, Merelbeke, Belgium) and then with Liver Digest Medium (Invitrogen). Subsequently, the digested liver was placed in Hepatocyte Wash Medium (Invitrogen). The cell suspension released from the liver was filtered through a 70-μm cell strainer (BD Falcon, Erembodegem, Belgium) and hepatocytes were separated from non-parenchymal cells via three low-speed centrifugation steps (5 minutes, 50g). Cell viability, measured using the Trypan Blue exclusion test, generally exceeded 90%. One million hepatocytes were injected into the spleen of 6- to 14-day-old uPA+/+-SCID mice. At selected moments, mice were bled, and plasma was stored at

−70°C until further analysis. [12] .

3.2.2 Quantification of Human Albumin

Human albumin in mouse plasma was measured using an in-house sandwich ELISA. Maxisorp Immunoplates (Nunc, Roskilde, Denmark) were coated with goat anti-human albumin antibodies (Bethyl Laboratories, Montgomery, TX). After blocking and washing, diluted samples or calibrators were added, and human albumin bound to the plate was detected with a HRP-conjugated goat-anti-human albumin antibody (Bethyl Laboratories). [12].

3.2.3 Detection and Quantification of Viral DNA/RNA and Proteins

HBV DNA and HCV RNA levels were quantified using the Cobas Amplicor HBV Monitor test and the Cobas Amplicor HCV Monitor test v2.0 (Roche Diagnostics, Mannheim, Germany), respectively. HBsAg and HBeAg were determined with the Axsym HBsAg V2 and the Axsym HBe 2.0 system (Abbott, Chicago, IL), respectively. The antigen levels were expressed as Signal/Noise values. [12].

3.2.4 Detection of Human Proteins in Chimeric Plasma

Fifty microliters unfractionated mouse EDTA plasma was used for a non-gel proteome analysis. The proteins were digested with trypsin, and combined fractional diagonal chromatography (COFRADIC™) was used to isolate the amino terminal peptides out of this complex peptide mixture.10 The isolated peptides were further analyzed by LC-MS/MS using a Q-TOF1 mass spectrometer (Micromass UK Limited, Cheshire, UK) and the obtained MS/MS spectra were linked to peptide sequences stored in a tailor-made database (http://www.proteomics.be/bioinfo/lm/dbtoolkit) containing human and murine full and sequentially ragged protein sequences,10 using the MASCOT database search engine (http://www.matrixscience.com). Peptides identified by a MASCOT score that exceeded the identity threshold score of MASCOT at the 95% confidence level were considered as positively identified. [12].

3.2.5 uPA-SCID Mouse Livers Used for Histopathological Evaluation

The livers of 5 uPA-SCID mice were used for extensive histological evaluation. The liver of a 2-week-old nontransplanted, noninfected uPA-SCID mouse was used as a reference. Two mice were killed 36 and 78 days after transplantation, respectively. One HBV- and one HCV-infected chimeric animal was killed 25 days and 41 days after infection, respectively. [12].

Chapter Four

Results andDiscussion

Chapter Four

4.1 Introduction

The previous chapter we overview of the proposed system approach that provides an efficient approach to resource allocation and also describes the design of the proposed system in detail and description of the steps of the research method and system . This chapter present the final results of the project.The Results of the Project

4.2 Plasma Analysis of Chimeric Mice

The success of human liver cell engraftment and expansion in the transplanted uPA+/+ transgenic SCID mice was evaluated by quantifying human albumin in mouse plasma at regular intervals. Figure (4.1) shows that human albumin concentrations reached a median level of 3 mg/mL by week 4 after transplantation and increased to 7 mg/mL by week 7. Thereafter the albumin levels remained quite constant until at least 14 weeks after transplantation. [13] .

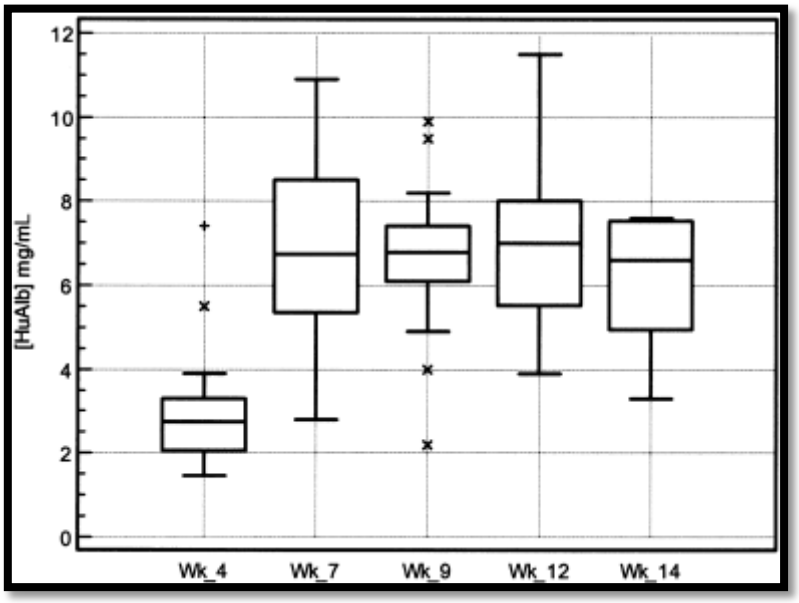

Figure 4.1 human albumin concentrations

4.2.1 Histological Studies of Uninfected Chimeric Livers Chimeric uPA-SCID Mice 36 and 78 Days After Transplantation.

Massive numbers of mature human hepatocytes were identified in the livers of transplanted mice. These could easily be discriminated from their murine counterparts by their larger size and the peculiar appearance of their cytoplasm (Fig. 4.2-A). The human hepatocytes were somewhat swollen and had a rarefied cytoplasm with wisps and small clumps of eosinophilic material in an otherwise empty-appearing cytoplasm. The cell membranes appeared mildly thickened. The empty-appearing areas of the cytoplasm on hematoxylin and eosin staining corresponded to areas of glycogen storage, as shown by periodic-acid-Schiff (PAS) staining (Fig. 4.2-B). The stainings for albumin, mitochondria, pan-cytokeratin, and CK18 confirmed the human origin of these hepatocytes (Fig. 4.2-C,F), and the cytoplasmic staining pattern was also in wisps and small clumps, indicating that the organelles were displaced and clumped together by the excessive glycogen accumulation. The morphological features of the hepatocytes are identical to the morphology of hepatocytes in all glycogen storage diseases, except type IV.11 This was confirmed by comparing our present findings with 4 archival clinical liver biopsy specimens from patients with glycogenosis and with descriptions of glycogenosis in the literature.[13] .

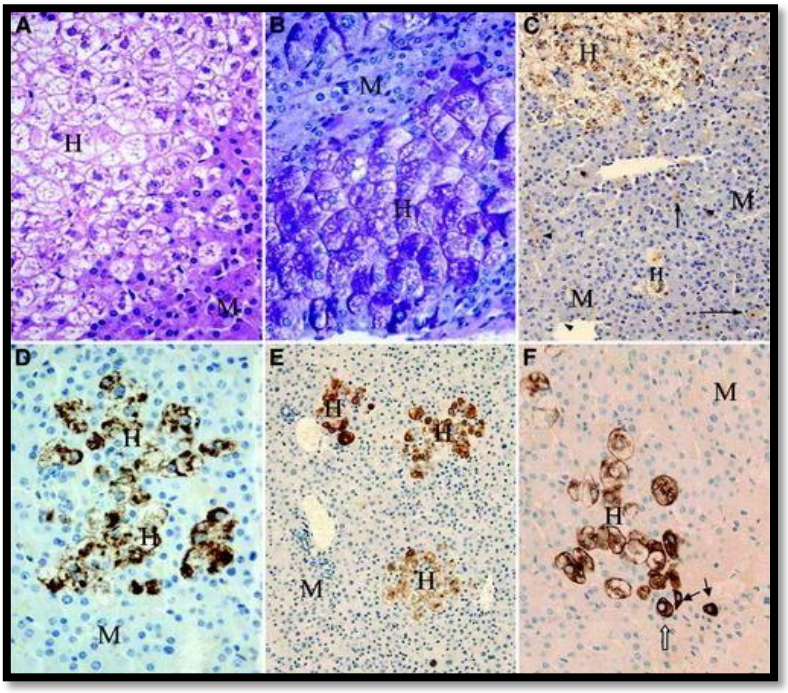

Figure 4.2 mature human hepatocytes were identified in the livers

Histology of a chimeric liver. (A) Hematoxylin and eosin staining easily allows identification of the human hepatocytes (H) within mouse (M) parenchyma. The cytoplasm of the human hepatocytes has an unusual pale and granular appearance, resembling the morphology of hepatocytes in glycogen storage diseases. (B) PAS staining shows that, in contrast to the negative mouse hepatocytes, glycogen accumulation is restricted to the cytoplasm of the human hepatocytes. (C) Staining for human albumin unveils the human origin of these pale hepatocytes. Several ceroid macrophages (arrows) also can be seen within mouse parenchyma. Despite a low background staining of the lumen of sinusoids and larger blood vessels (arrowheads), mouse hepatocytes never stain positive for human albumin. Clusters of human hepatocytes can also be visualized with antibodies specific for human mitochondria (D), human pan-cytokeratin (E), and human CK18 (F). Human hepatic progenitor cells (black arrows) and intermediate hepatocyte-like cells (white arrow) were also observed (F). (Original magnifications: A, B, D, and F, ×400; C and E, ×200)

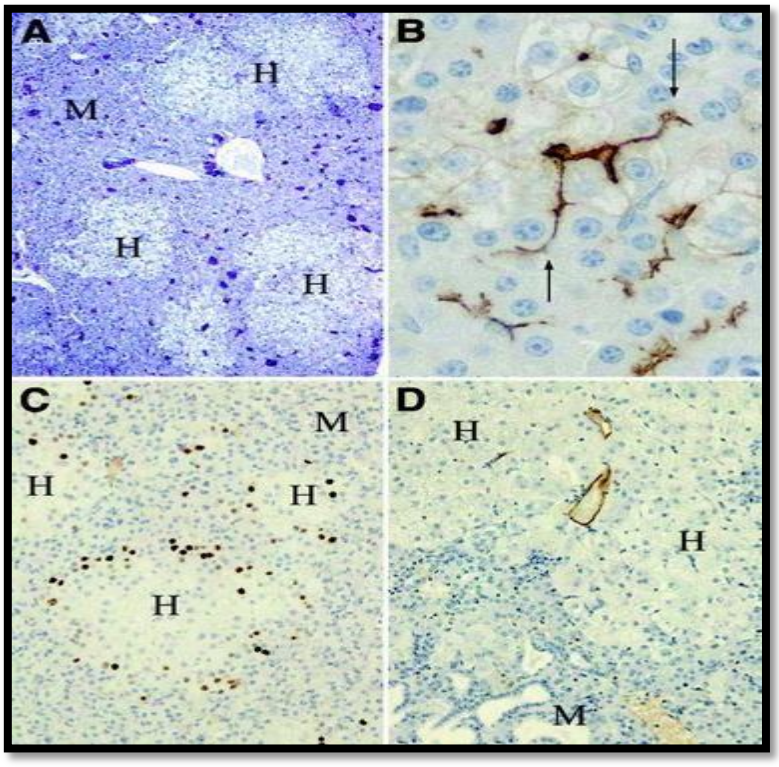

Figure 4.3 Histology of a chimeric liver

4.3 Discussion

Recently, two groups independently created chimeric mice harboring human hepatocyte grafts and successfully induced HBV7 and HCV8 infections in these animals. Both groups provided convincing evidence for solid hepatocyte engraftment and active viral replication but paid less attention to the functional integrity and structural organization of the transplanted hepatocytes in the xenogeneic environment. We wanted to fill this gap and present here a detailed description of the functional and morphologic characteristics of the chimeric liver before and during active HBV and HCV infections.

To evaluate the human hepatocyte graft-take and expansion in uPA+/+-SCID mice, the human albumin concentration in mouse plasma was monitored at regular intervals. In successfully transplanted mice, the albumin level reached a plateau value of approximately 7 mg/mL (median value) around week 7, and this level remained unchanged in the weeks that followed. Although the human albumin level is a reliable marker of the integrity and functional status of the human hepatocytes, we performed a proteomic analysis10 of the mouse plasma and demonstrated the presence of 21 additional and less abundant human proteins. Most of these proteins are known plasma proteins synthesized by the liver. Apart from these “classical” human plasma proteins, some human proteins with a membrane or nuclear localization could also be detected. Their presence in the plasma may be due to membrane turnover or release from dying hepatocytes. The presence of these atypical plasma proteins in our chimeric mouse plasma is not unexpected because such proteins are also found in the plasma of healthy blood donors.17, 18

Chapter Five

Conclusions

Chapter Five

5.1 Introduction

In the previous chapter, we discussed the final results of the research. In this chapter we will discuss the conclusion of the entire research and future works.

5.2 Conclusion

The nb/nb mouse with a hereditary hemolytic anemia is an animal model of hemolysis-induced gallstone disease. These anemic mice have hepatomegaly and form calcium bilirubinate gallstones. We undertook this study to: (a) examine the histopathology of the liver and gallbladder in nb/nb mice and (b) assess the influence of hemolysis per se on liver and gallbladder histology by transplanting nb/nb bone marrow into another genotype W/Wv. Livers and gallbladders obtained from male nb/nb and control mice of similar age were stained with hematoxylin and eosin. Gallbladders were also stained with alcian blue (pH 2) and periodic acid-Schiff for acidic and neutral glycoproteins, respectively. Volume densities of the extralobular (blood vessels) and lobular (hepatocytic and sinusoidal) components of the liver and glands of the gallbladder neck were determined by standard morphometric techniques.[

References

[1] . Trotman, Bruce W., et al. "A morphological study of the liver and gallbladder in hemolysis-induced gallstone disease in mice." Hepatology 2.6 (1982): 863-869.

[2] . Trotman, B. W., Bongiovanni, M. B., Kahn, M. J., & Bernstein, S. E. (1982). A morphological study of the liver and gallbladder in hemolysis-induced gallstone disease in mice. Hepatology, 2(6), 863-869.

[3] . FUJII, Yasuhisa, et al. Morphological and histochemical analyses of living mouse livers by new 'cryobiopsy'technique. Microscopy, 2006, 55.2: 113-122.

[4] . Vesselinovitch, S. D., N. Mihailovich, and K. V. N. Rao. "Morphology and metastatic nature of induced hepatic nodular lesions in C57BL× C3H F1 mice." Cancer research 38.7 (1978): 2003-2010.

[5] . Heckel JL, Sandgren EP, Degen JL, Palmiter RD, Brinster RL. Neonatal bleeding in transgenic mice expressing urokinase-type plasminogen activator. Cell 1990; 62: 447–456.

[6] . Bakiri, Latifa, and Erwin F. Wagner. "Mouse models for liver cancer." Molecular oncology 7.2 (2013): 206-223.

[7] . Bakiri, L., & Wagner, E. F. (2013). Mouse models for liver cancer. Molecular oncology, 7(2), 206-223.

[8] . BAKIRI, Latifa; WAGNER, Erwin F. Mouse models for liver cancer. Molecular oncology, 2013, 7.2: 206-223.

[9] . Bakiri, Latifa, and Erwin F. Wagner. "Mouse models for liver cancer." Molecular oncology 7.2 (2013): 206-223.

[10] . Tateno, Chise, and Yuha Kojima. "Characterization and applications of chimeric mice with humanized livers for preclinical drug development." Laboratory Animal Research 36.1 (2020): 1-9.

[11] . Tateno, C., & Kojima, Y. (2020). Characterization and applications of chimeric mice with humanized livers for preclinical drug development. Laboratory Animal Research, 36(1), 1-9.

[12] . Fausto N, Campbell JS. The role of hepatocytes and oval cells in liver regeneration and repopulation. Mech Dev 2003; 120: 117–130.

[13] . Fox IJ, Roy-Chowdhury J. Hepatocyte transplantation. J Hepatol 2004; 40: 878–886