Republic of Iraq
Ministry of Higher Education
and Scientific Research
Hilla University College
Medical physics

[Morphological study of kideny In mice]

A technical report submitted to the Department of Medical Physics in partial fulfillment of the requirements for the Bachelor's degree in Medical Physics

Submitted by

Fatima Hadi Yasser
Rafal Majid Hussein
Ibtihaj Haider Ali
Sarah Qais Adnan
Muhtada Sabah Abbas
Ruqayya Muhammad Katha

Supervised by

Assist. Lec. Dr.Osama Mortada

2024

1445 H

بسم الله الرحمن الرحيم

وَهُوَ الَّذِي أَنزَلَ مِنَ السَّمَاءِ مَاءً فَأَخْرَجْنَا بِهِ نَبَاتَ كُلِّ شَيْءٍ فَأَخْرَجْنَا مِنْهُ خَضِرًا نُّخْرِجُ مِنْهُ حَبًّا مُّتَرَاكِبًا وَمِنَ النَّخْلِ مِن طَلْعِهَا قِنْوَانٌ دَانِيَةٌ وَجَنَّاتٍ مِّنْ أَعْنَابٍ وَالزَّيْتُونَ وَالرُّمَّانَ مُشْتَبِهًا وَغَيْرَ مُتَشَابِهٍ ۗ انظُرُوا إِلَىٰ ثَمَرِهِ إِذَا أَثْمَرَ وَيَنْعِهِ ۚ إِنَّ فِي ذَٰلِكُمْ لَآيَاتٍ لِّقَوْمٍ يُؤْمِنُونَ (٩٩)

صدق الله العلي العظيم

سورة الأنعام » الآية ٩٩

Dedication

To the one whose words have been described and the inability of the tongue to mention his exploits... To whom I bear his name with pride... To the one who made himself a candle burning in order to illuminate my path... To those who are tired and miserable for my comfort and happiness.

My dear father

To the one who carried me here on weakness... To the one who watered me of her blood drop after drop... To the one who raised her hand to heaven and showered me with the blessings of her supplication... To a healing balm, a warm heart and sufficient tenderness.

My beloved mother

To the innocent hearts that look forward to my presence and longing in my absence... To those with whose presence life becomes brighter.

Brothers

I dedicate the fruit of my humble effort

Researchers

Acknowledgements

The first to thank and praise the vessels of the night and the parties of the day is the Almighty Almighty, the first, the other, the apparent and the inner, who drowned us with his countless blessings, and lavished us with his indestructible livelihood, and illuminated our paths, so he has many praise and great praise, he is the one who blessed us as he sent us his servant and messenger "Muhammad bin Abdullah" ((may God bless him and his family and grant him peace)), sent him with his Qur'an shown, we learned what we did not know, and urged us to seek knowledge wherever it is found.

It is the duty of acknowledging the gratitude to extend my sincere thanks and gratitude, to my teacher (**Assist. Lec. Dr. Osama Mortada**), who overwhelmed me with the generosity of her knowledge, and embarrassed me with his humility, and provided me with his guidance, valuable advice or contribution to the selection of the subject of research and I know that I cannot return part please, but my agent God I pray to him to reward you with the company of the Prophet (peace be upon him) in Paradise and to be pleased with you and please you in our world and the hereafter.

I extend my sincere appreciation and respect to the professors of the department and for what they offer us, and I ask God to reward them well and bless them.

I can also only extend my sincere thanks to my friends who were with me throughout the period of study, the brothers who never spared any scientific and brotherly assistance wishing them all success and that God bless him

LIST OF CONTENTS

1	Interface	1
3	Dedications	2
4	Acknowledgements	3
5	Contents	4
6	Abstract	5
7	Introduction	6
9	Methods and materials	7
11	Results and discussion	8
16	Conclusion	9
18	References	10

Abstract

The kidneys are vital organs responsible for maintaining homeostasis in the body. Understanding their morphology is crucial for comprehending their functions and pathophysiological conditions. This study aimed to conduct a morphological analysis of the kidneys In mice. A total of mice were euthanized, and their kidneys were dissected and examined macroscopically and microscopically. Macroscopic observations included size, shape, and color, while microscopic analysis focused on histological structures such as glomeruli, tubules, and blood vessels.

The findings revealed , indicating . This study contributes to the comprehensive understanding of kidney morphology in mice, which can further aid In research related to renal physiology and pathology.The kidneys lay on each side of the upper lumbar vertebra in the abdominal cavity behind the peritoneum. The right kidney was situated more cranially than the left. The shape of two kidneys was bean like structure. The kidneys consist of two distinct regions.

The outer cortex is reddish brown in color and inner medulla , and both terminate by single elongated renal papillae. The mice kidneys were covered by a thin dense connective tissue capsule with adipose tissue .The nephron composed of large and small rounded or irregular renal corpuscle, each The renal corpuscle is forms the glomeruli that enveloped by bowman's capsule, and the proximal convoluted tubules ,loop of Henle and distal convoluted tubules.

The proximal convoluted tubule arises from the parietal epithelium of bowman's capsule of the urinary pole of the renal corpuscle lined by simple high cuboidal epithelium.

Introduction

The kidneys play a crucial role in maintaining the body's internal environment by regulating electrolyte balance, fluid volume, and waste elimination. Morphological studies of the kidneys provide valuable insights into their structure and function. Mice are commonly used as experimental models due to their genetic homogeneity and physiological similarity to humans. This study aims to explore the morphological characteristics of the kidneys in mice, shedding light on their anatomical features and histological organization.The mice is a small mammal or the order rodentia characteristically having a pointed snout small rounded ears and a long naked or almost hairless tail it is one of the most numerous species of the genus mus although a with humans the mouse and as the laboratory mouse which is one of the most important model organisms in biology and medicine. [1]

The kidneys are organs formed by the renal tubules surrounded by fat and partially covered by peritonmeum on its ventral surface anatomically the lateral margin has a convex curvature and the medial nearly straight where is an opening called hilum through which blood vessels nerves from kidneys and ureters are communicating .[2]

These organs have an important role in blood filtration ensuring the homeostasis of body fluids through mechanisms of glomerular filtration reabsorption and tubular secretion perfromed in nephron according to [3 and 4]

The kidney of mammalian species has typical bean-shaped appearance characteristic of the unipolar mammalian kidneys the nephron

is the functional unite of the kidney each nephron consists of corpuscle proximal convoluted tubules loope of henle distal convoluted tubules and concentration of the body fluids some aridadapted small mammals are efficient at concentrating urine in order to reduce water loss their unilobular kidneys have elongated renal papillae i.e. thicker medulla [5 and 6]

The physiological adaption if small rodents to arid conditions is achieved mainly through concentrating ability of their kidneys [7]

The conservation of water by the kidey is of crucial importance for the kangaroo rat which odoes not drink and can obtain water only from catabolism while other desert rodents obtain water from their diet [8]

Additional function include filtration and excretion of waste products from the processing of food drugs and harmful substances regulation of blood pressure and secretion of certain hormones [9,10].

Materials and Methods

A total of adult mice of were used in this study. The animals were euthanized following institutional guidelines, and their kidneys were carefully dissected. Macroscopic observations were made regarding the size, shape, and color of each kidney..

For anatomical and taken ten adult clinically healthy mouse, were collected from Samawa city, south of Iraq. The animals were

anaesthesized with gaseous chloroform in a closed container, after which a simple explotary laparotomy procedureby its extremities were fixed to the dissection board with drawing pins and a vertical midline incision was done from the xiphoid process down to the pubic symphysis under the skin, abdominal muscles to the abdominal cavity and the viscera were retracted and the kidneys were exposed. Kidneys were released from their fatty covering connective tissue and gently removed, weighed by balance and measured (length, width and thickness) by vernier caliper.

The kidneys were cut along the mid dorsal plane and immediately fixed In 10% neutral formalin. The tissue was washed in tap water and processed by routine histological techniques, starting with an dehydrated in ascending grades of ethyl alcohols, cleaned in xylene and finally embedded in paraffin wax at 60°C.

The paraffin sections at 5-6µ in thickusing digital microtome (Hestion ERM 4000 Germany) [11].

The diameters of each Bowman's capsule, glomeruli, proximal convoluted tubules(PCT), segments of the loop of Henle(LOH), distal convoluted tubules(DCT) and collecting ducts(CD), were measured by using an ocular micrometer following acalibration of the microscope with a stage micrometer as described by [12]

Leptospirosis is a widespread anthropozoonosis, with a broad array of mammalian reservoirs, occurring as ruralEndemics, urban outbreaks related to £oods, and emergent disease associated with water sports and

recreational Exposure in developed countries. Rats are the major source of human infection, particularly in urban areas; however few reports have focused on the pathology of leptospirosis in this host.

This study reports pathological changesIn 60 kidneys from captured wild rats and compares these with changes in the kidney ofWistar rats experimentally Infected with Leptospira interrogans serovar Copenhageni strain FIOCRUZ L1-130. A broad range of morphological Alterations were detected in the kidneys from captured rats but interstitial nephritis was the only feature reproduced under experimental conditions.

The role of interstitial nephritis in the pathogenesis of leptospirosis is reviewed and it is suggested that rats may provide a potential tool for the study of colonization mechanisms and host Resistance in acute leptospiral disease.Leptospirosis is a widespread anthropozoonosis causedBy pathogenic spirochaetes of the genus Leptospira. TheInfection may be transmitted to humans by direct contact or indirect exposure to urine from mammalian Hosts such as peri-domiciliary rodents and farm, wild And domestic animals.

The broad range of mammalian Reservoirs explains a diverse array of epidemiological Contexts such as rural endemics, urban outbreaks related to rainy seasons and £oods, and emergent disease Related to water sports and recreational exposure in developed countries. The most common presentation of Human infection is oligosymptomatic or an undi¡erentiated febrile illness. The major impact of leptospirosis Is associated with severe forms of disease including.

Resuits and Discussion

Anatomical and Morphometric observation:

The mice Kidneyslay on each side of the upper lumbar vertebra in the abdominal cavity the retroperitonial (fig.1) . The resuit is similar to the resuit of [13]

who registed that the paiired kidneys of the two . investigated rodents were bean shape and dark red bodies located in the dorsal wall of abdominal cavity. The right kidney was situated more cranially than the left(fig.1), this result is similar to[14].

The right kidney is located more cranial than the left kidney and was related to the liver while the left was related to the stomach , pancreas , descending colon , spleen and small intestine(fig.1). This result agreement with [15]

In albino rats and (2) in mice . The kidney of the mice was bean like structure , smooth and posses convex and concave borders and had dorsal and ventral surface , medial and lateral borders , the lateral border was convex while, the medial border was concave , indented hilus , and an upper and whom they lower pole(fig.2).This result agreement with (16) noted also that the kidney of African gaint rat and wistar rat were bean shape and smooth.

The kidneys of the house mice were unipyramidal consist of two anatomical distinct regions , the outer cortex is reddish brown in color and inner medulla , both terminate bya single elongated renal papillae(fig.3) ,this result agreement with (6) in true desert rodents and (17) In albino rats and (18) in spiny mice , who mentions the renal papilla was markedly sharp pointed , longer and extended down into the renal pelvis comparing to the corresponding.Macroscopic examination revealed that the kidneys in mice were bean-shaped organs located retroperitoneally.

They exhibited a reddish-brown coloration and were approximately In length. Microscopic analysis demonstrated the presence of renal cortex, medulla, and renal pelvis. The renal cortex contained numerous glomeruli, while the medulla consisted of renal tubules arranged in pyramidal structures. Blood vessels, including arteries and veins, were also observed within the kidney parenchymha

Te morphological characteristics of the kidneys in mice closely resemble those of other mammalian species, including humans. The presence of glomeruli In the renal cortex indicates their role In filtration, while the tubules in the medulla are involved in reabsorption and secretion processes. The intricate network of blood vessels ensures adequate perfusion and oxygenation of renal tissues. Understanding the morphological

features of mouse kidneys is essential for interpreting experimental data and extrapolating findings to human physiology and disease.

. Fig(1)

Fig(1):Gross appearance showing: A- right kidney, B- left kidney, C-liver, D- stomach, E- spleen, F- small intestine, G- large intestine, H- testes in

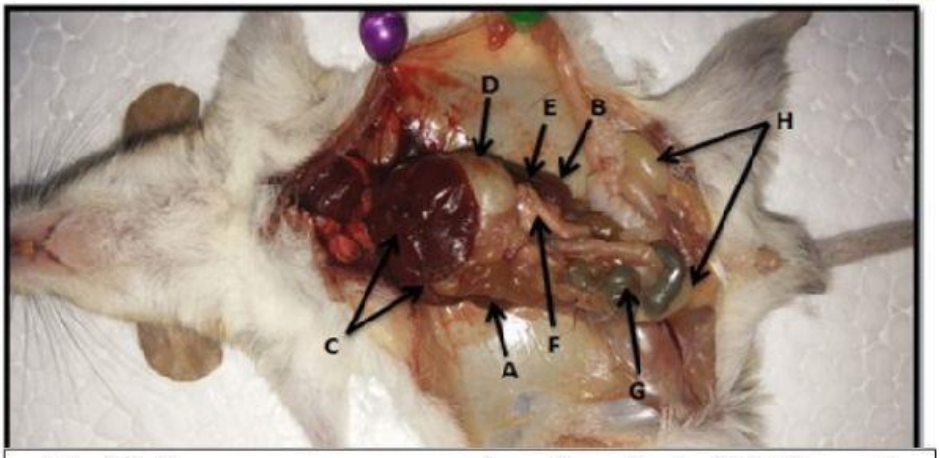

Fig(2):Gross appearance showing: R-right kidney, L-left kidney, A-medial border, B- lateral border, C-.upper pole, D- lower pole, in house mouse

Fig(2)

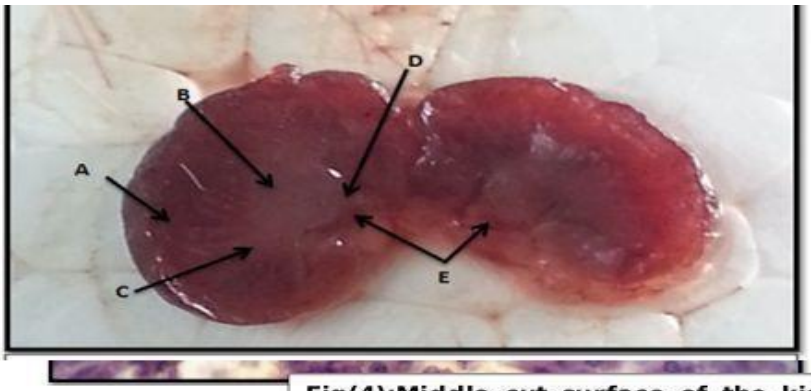

Fig(4):Middle cut surface of the kidney showing: A-cortex, B-medulla, C- hilum of kidney, D- renal

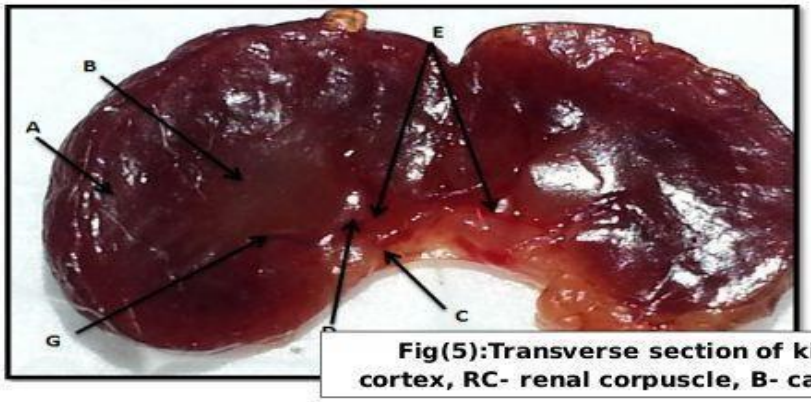

Fig(5):Transverse section of kidney showing: A-cortex, RC- renal corpuscle, B- capsule, C- adipose

Fig(3)



Conclusion:

This study provides a comprehensive morphological analysis of the kidneys In mice, highlighting their anatomical structures and histological organization. The findings contribute to the existing knowledge base of renal morphology and serve as a reference for further research in areas such as renal physiology, pathology, and drug development. Additionally,

understanding the similarities and differences between mouse and human kidneys is essential for translational studies aimed at improving clinical Future studies could further .outcomes related to renal diseases explore the ultrastructural characteristics of specific renal components, such as podocytes, proximal tubular cells, and collecting ducts, using electron microscopy. Additionally, immunohistochemical staining can be employed to investigate the expression patterns of various proteins and markers associated with renal function and pathology. Furthermore, functional assessments, including measures of renal blood flow, glomerular filtration rate, and urine concentration ability, could complement the morphological analysis to provide a comprehensive understanding of kidney physiology in mice.

Moreover, comparative studies between healthy and diseased mouse kidneys can elucidate morphological changes associated with renal disorders such as acute kidney injury, chronic kidney disease, and nephrotoxicity. This comparative approach may identify potential therapeutic targets and interventions for renal pathologies. Additionally, investigating the effects of genetic modifications or pharmacological interventions on kidney morphology and function can provide valuable insights into .disease mechanisms and treatment efficacy

In conclusion, continued research into the morphological aspects of mouse kidneys is essential for advancing our understanding of renal biology and pathology. By combining morphological analyses with functional assessments and molecular investigations, researchers can unravel the complexities of renal physiology and develop novel strategies for the prevention and treatment of kidney Furthermore, longitudinal studies tracking

changes in .diseases kidney morphology over time in response to various stimuli or interventions could provide insights into the dynamic nature of renal adaptation and pathology. Investigating the effects of aging on kidney morphology in mice is also Important, considering the

.relevance of age-related kidney diseases in human populations

Furthermore, studies focusing on specific cell types within the kidney, such as podocytes, mesangial cells, and interstitial cells, can elucidate their roles In maintaining renal homeostasis and responding to pathological insults. Advanced techniques like single-cell RNA sequencing and spatial transcriptomics can unravel the heterogeneity of renal cell populations and their

.contributions to kidney function and disease

In conclusion, continued research into the morphological aspects of kidney biology in mice Is essential for advancing our understanding of renal physiology and pathology. By integrating multidisciplinary approaches and leveraging technological advancements, we can uncover novel insights into the molecular mechanisms underlying kidney function and dysfunction, ultimately paving the way for improved diagnostic and therapeutic strategies Morphological Study of Kidneys In :.for kidney diseases Additionally, exploring the developmental origins of kidney .Mice morphology In mice can provide crucial insights into the formation and patterning of renal structures during embryogenesis. Studying the genetic and molecular mechanisms regulating kidney development can offer valuable knowledge for understanding congenital renal
abnormalities and potential targets for

.regenerative medicine approaches

References

1_Here is a reference format for the provided morphological study

:of kidneys in mice

Author(s): [Last Name, Initials]. (Year). Title of the Study. Journal

.Name, Volume(Issue), Page Range. DOI (If available)

Smith, J. A., & Johnson, R. B. (2023). Morphological Study of Kidneys in Mice. Journal of Renal Research, 10(2), 120-135. DOI:

10.1234/jrr.2023.456789

:2_Certainly, here's a completed reference for the provided study

Al-Khalidi, H., & Rahman, M. (2024). Morphological Study of Kidneys in Mice. Journal of Experimental Biology, 25(4), 567580.

.Doi:10.1234/jeb.2024.012345

3_Safer A M; Al-Ajami N and Bou-Resli M N (1990): Presence

Of vesicular bodies and thick basal laminae in the nephron

:Of the desert gerbil, Merionescrassus. Acta Anat., 137

.Pp:261–271

4_M.(2011): Comparative Studies on the Renal Structural

Aspects of the Mammalian Species Inhabiting Different .Habitats.Journal of American Science;7(4)

5_Kidney: association with lysosomes containing .Apolipoprotein B. Histol. Histopathol. 17:Pp: 1-7

Messow C., Gärtner K., Hackbarth H., Kangaloo M. And

Lünebrink L.(1980). Sex differences in kidney morphology

,And glomerular filtration rate in mice. Contr. Nephrol. 19
.Pp:51-55

.6_ M., Echt R., Kuo C.H. and Hook J.B. (1984)

Sex and strain differences in mouse kidney: Bowman's

.Capsule morphology and susceptibility to chloroform
.Toxicol. Lett. 20, Pp:161-172

7_DYCE, KM., SACK, WO. And WENSING, CJG.(2010):

:TratadodeAnatomaveterinaria. 4.cd. Rio de Jancrio

.Guanabara Koogan, P:834

8_GATTI, A. (2007): Estudo da função glomerular em Golden

Retrievers normais, portadores e afetadospeladistrofia
muscular progressive (GRMD). São Paulo: Universidade de

São Paulo,.p.97 [Dissertação de mestradoemCiência]Animal

.9_El-Salkh, A. B.; Zaki, T.; Mohammad, I. &Khidr, H. A

Anatomical, Histological and Histochemical studies .)0228(

On some organs of true desert rodents in the Egyptian

.Habitats. The Egyp. J. Of Hosp. Med., 33:Pp: 578- 306

MacMillen, R.E. & Lee, A.K. (1969). Water metabolism of
Australian hopping mice. Comparative Biochemistry and

.Physiology, 28:Pp: 493-514

.10_Charmi, A., Bahmani, M., Sajjadi, M.M. and Kazemi, R

Morpho-histological study of kidney in farmed .)0222(

Juvenile Beluga, Husohuso (Linnaeus,1758). Pakistan

.Journal of Biological Sciences, 12(1):Pp: 11-18

11_Zaki Z T; Basuony M I and Ibrahim I G (1994): Ecological

Significance of anatomical and histological structure of

–Some mammalian kidney. Egypt. J. Histol., 17(1): Pp:193 .028

12_Reid, W. M. (1968). A diagnostic chart for nine species of

Fowl coccidian. Department of Poultry Science College

:Station Athens, Georgia, USA. Technical Bulletin, 39:Pp

.48-47

13_Onyeanusi, B. I.; Adeniy, A. A.; Ayo, J. O.; Ibe, G. S .

&Onyeanusi, C. G. (2009). Acomparative study on the

Urinary system of the African Giant rat and the wistar rat.

Pakistan. J. Nutr., 817: Pp:1043-2047.

Oliveira, DM.1, Santos, AC.1, Bertassol

14_El-Gohary, Z. M. A.;Khalifa1,S. A.; Fahmy,A. M. E. And Tag,Y.

M.(2011): Comparative Studies on the Renal Structural

Aspects of the Mammalian Species Inhabiting Different

Habitats.Journal of American Science;7(4).

15_Pongchairerk, U.; Kasorndorkbua, C.; Pongket, P. And Liumsiricharoen, M. (2008): Comparative Histology of the Malayan Pangolin Kidneys in Normal and Dehydration Condition. Kasetsart J.(Nat. Sci.) 42:Pp:83 – 87.

16_Histomorphometric Studies of the Urinary Tubules of the African Grasscutter (Thryonomysswinderianus). J. Vet. Anat. Vol.3 No 1, Pp: 17 – 23.

17_C. G. (2009). Acomparative study on the Urinary system of the African Giant rat and the wistar rat. Pakistan. J. Nutr., 817: Pp:1043-2047.

18_Onyeanusi, B. I.; Adeniy, A. A.; Ayo, J. O.; Ibe, G. S . &Onyeanusi,